

# **Idiopathic ventricular tachycardia in 21-year-old man with short QT interval and early repolarization syndrome**

**S. Dolginina, S. Garkina, I. Tyurina, O. Rubanenko, S. Khokhlunov, D. Duplyakov**

**Samara, Russia**

# BACKGROUND

- **Idiopathic ventricular tachycardia (VT) refers to VT occurring in structurally normal hearts**
- **It is usually a benign arrhythmia with good prognosis that can be managed with antiarrhythmic agents and is often cured using catheter ablation**
- **It is sometimes diagnosed in young adults with early repolarization (ER) pattern on ECG which has been long considered as a benign electrocardiographic manifestation**
- **Concomitant short QT syndrome is probably associated with both atrial and ventricular arrhythmias and life-threatening events**
- **Due to lack of clinical studies the long-term outcome in this group remains uncertain**

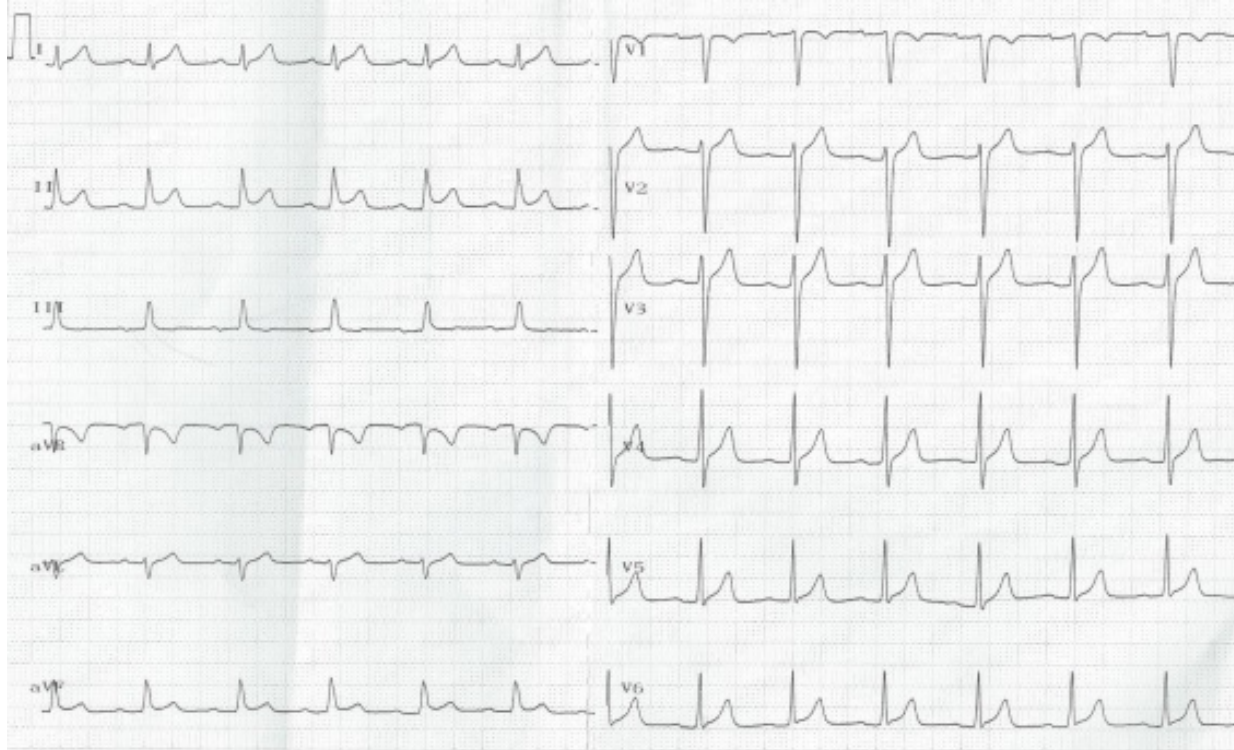
# CASE REPORT

- **21-year-old male**
- **recurrent palpitations, dyspnea and lightheadedness**
- **medical student, non-smoker**
- **history of rare episodes of palpitation during last 6 months without syncope**
- **unremarkable family history was while his grandmother had dead born child**
- **normal exercise tolerance (played soccer 1-2 times a month)**
- **no recent viral illness**
- **severe psychologic stress during exams within last two days**
- **no medication before admission**

# PHYSICAL EXAMINATION

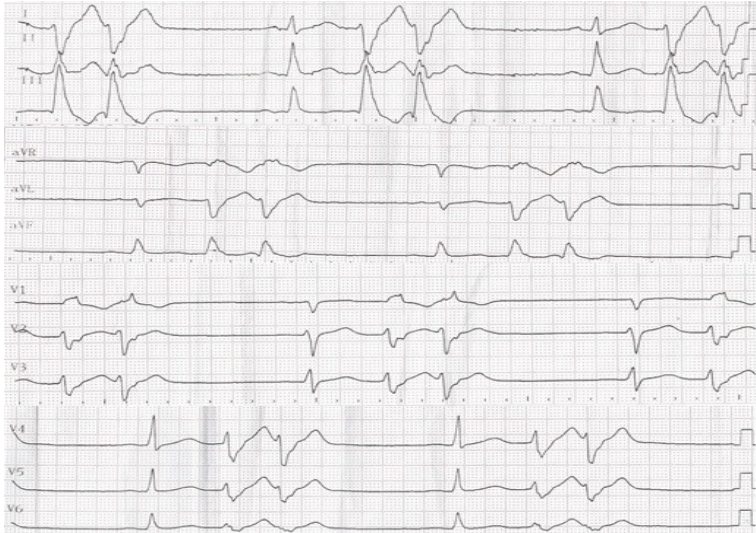
- **vesicular respiration without rales**
- **respiratory rate 18-20 pm**
- **normal cardiac borders**
- **tachycardia with HR 114 bpm**
- **blood pressure 125/80 mm Hg**
- **in ED blood tests revealed elevated triglycerides**
- **other lab tests including brain natriuretic peptide, D-dimer and cardiac troponin were normal**

# ECG on admission

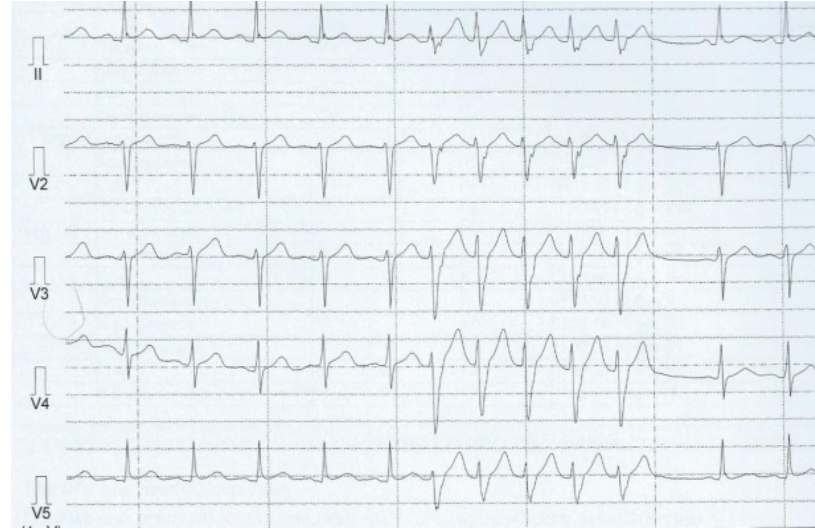


**Sinus rhythm with signs of early repolarization syndrome and corrected QT interval of 28 ms**

# ECG on admission



**Fig.2**



**Fig.3**

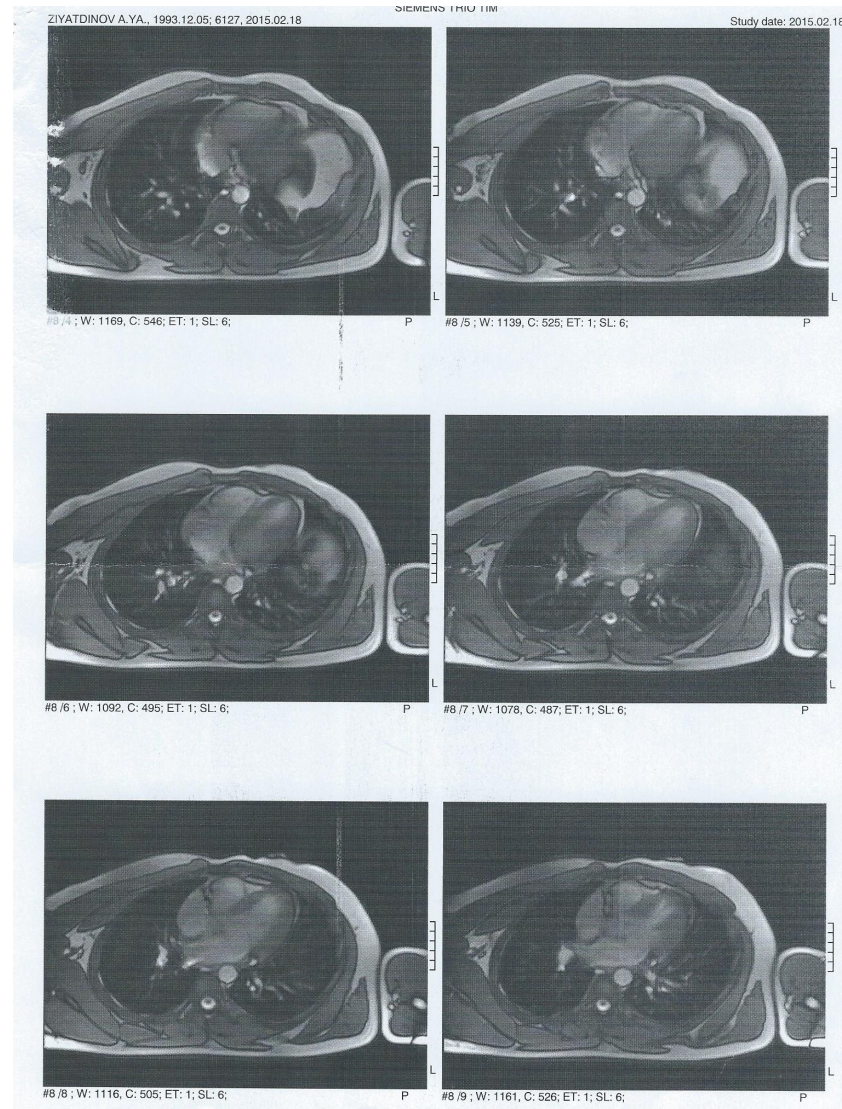
**During his evaluation in the ED palpitations recurred and ECG showed frequent ventricular premature complexes (fig 2) transforming into non-sustained VT (fig 3) with QRS duration of 0.16 ms that was spontaneously converted to sinus rhythm.**

# DIAGNOSTICS

- **Echocardiogram didn't show any abnormalities, estimated left ventricular ejection fraction was 63%.**
- **Holter monitoring revealed infrequent VE and four episodes of asymptomatic non-sustained monomorphic VT and demonstrated short corrected QT interval under 32 ms within 2.5 hours**
- **MRI scan showed structurally normal heart while genetic tests didn't reveal ARVC mutation and patient was consequently diagnosed idiopathic VT**



# MRI





# Dynamics

- **Patient was started metoprolol 50 mg a day and didn't experienced palpitation during hospitalization**
- **He was discharged 7 days after admission in stable condition and was recommended to continue low doses of metoprolol and consider catheter ablation in case of frequent recurrence of VT.**
- **During 10 months follow up he remained asymptomatic**
- **Ambulatory screening of other family members didn't reveal any cardiac abnormalities**

# Discussion

- **This clinical case demonstrates a wide QRS complex tachycardia in previously healthy young man without any predisposing cardiovascular risk factors except for stress.**
- **There was no recent viral infection or intoxication and lab findings didn't reveal inflammatory process. Considering clinical data and normal echo parameters the diagnosis of myocarditis or congenital heart disease was hardly probable.**
- **Nevertheless he may potentially have genetic disorder as his family history included dead born child. His ECG on admission demonstrated sinus rhythm and short QT syndrome which also could be genetically determined.**

# Short QT & ER syndrome

- **Clinical manifestations of SQTS may include palpitations, pre-syncope and syncope or even sudden cardiac death due to ventricular arrhythmias**
- **Some clinical case descriptions of combination between a short QT interval ( $< 32$  ms) and VT in young adults were reported**
- **Classical ERS with ascending ST-segment elevation is a frequent electrocardiographic finding, seen in 1% to 30% of the general population and is supposed to be benign.**
- **Localization of ER pattern in inferior leads combining with SQTS may have likely unfavourable prognosis as the patient began to experience symptoms of palpitation during last 6 months**

# CLINICAL CHALLENGES

- **We didn't perform cardiac catheterization and coronary angiography but possible diagnosis of Takotsubo cardiomyopathy was excluded due to absence of apical ballooning syndrome**
- **Although ECG pattern was not typical for right ventricular outflow tract tachycardia, cardiac MRI and genetic testing were performed to rule out arrhythmogenic right ventricular dysplasia and the results were negative**
- **In the absence of congenital heart disease and structural abnormalities VT in this patient appeared to be idiopathic.**
- **Catheter ablation was not performed due to short duration (8-10 complexes) of tachycardia and spontaneous conversion to sinus rhythm.**

# LEARNING POINTS

- **Ventricular tachycardia in a young population without clinical evidence of heart disease may be the first manifestation of cardiomyopathy or genetically determined channelopathy**
- **Idiopathic VT is likely diagnosed in the absence of structural cardiac abnormalities and others predisposing factors**
- **Treatment of ventricular tachycardia is recommended in any symptomatic patient and should be considered in asymptomatic individuals with idiopathic VT associated with short QT syndrome and ER pattern on ECG due to estimated high risk of life-threatening arrhythmic events**



**THANKS FOR YOUR ATTENTION!**

*Samara*