VENICE ARRHYTHMIAS 2015
MEXICAN CORNER
ELECTROCARDIOGRAPHY OF CLINICAL ARRHYTHMIAS

ECG AND HOLTER MONITORING IN ANDERSEN-TAWIL SYNDROME

Dr. Manlio F. MARQUEZ MURILLO
Instituto Nacional de Cardiología "Ignacio Chávez"
Mexico City, Mexico

OVERVIEW

1. Main clinical characteristics
2. 12-lead ECG features
3. Ventricular arrhythmias

PART I

MAIN CLINICAL CHARACTERISTICS

ANDERSEN-TAWIL SYNDROME

- ATS is type 7 of congenital LQTS and is caused by mutations in the gene KCNJ2 that encodes a protein that forms the rectifier potassium channel **Kir2.1**

- ATS is characterized by:

Periodic paralysis	Ventricular arrhythmias	Prolonged Q–U interval,	Mild facial or skeletal abnormalities

Initially ventricular arrhythmias were thought to be benign

Sudden cardiac death has been increasingly reported

Márquez MF, et al. (2015). Síndrome de Andersen-Tawil : una revisión del diagnóstico genético y clínico con énfasis en sus manifestaciones cardíacas. Archivos de Cardiología de México, *84*(4), 278–285.

EPIDEMIOLOGY

The disease is rare, with an estimated prevalence of **1/1'000,000**

38 cases in **Poland**

Prevalence in **England** 0.08/100,000.

Canún et al (1999) **Mexico**: 3-generation family

Zhang et al (2005) **US** 96 cases (12 countries)

Kostera-Pruszczyk , et al. (2014). Andersen-Tawil syndrome: Report of three novel mutations and high risk of symptomatic cardiac involvement. *Muscle & Nerve*, (February), 192–196.

EPIDEMIOLOGY

SCD (Zhang, 2005): 96 ATS1 patients

12 countries

The prevalence was higher in women

Hx of cardiac arrest 3/96 (<3%).

Family hx of SCD 4/33 (12%) kindreds

Zhang et al.(2005). Electrocardiographic features in Andersen-Tawil syndrome patients with KCNJ2 mutations: Characteristic T-U-wave patterns predict the KCNJ2 genotype. *Circulation*, *111*(21), 2720–2726.

PATHOPHYSIOLOGY

Mutation with a dominant negative effect: transversion (change of adenine for thymine) in nucleotide 440.

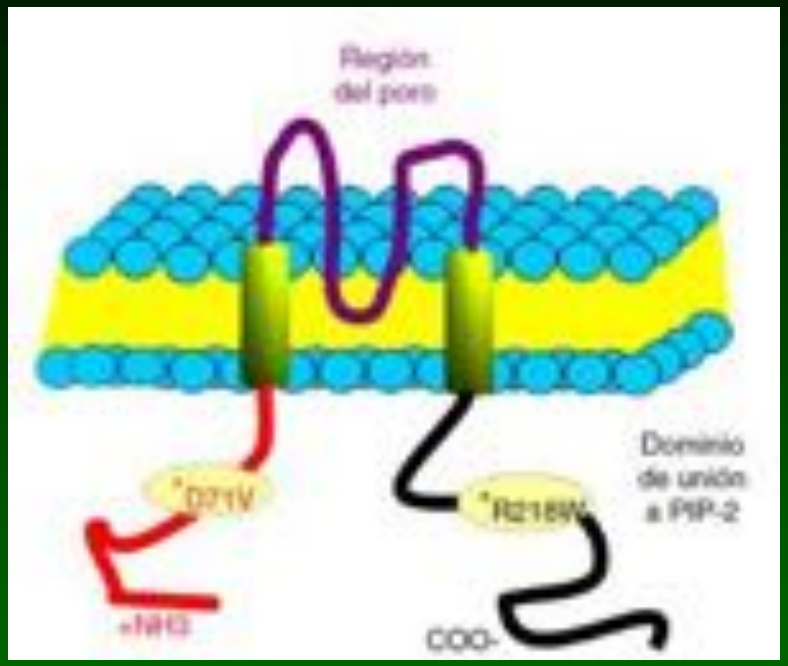

Affected gene is KCNJ2, which forms the inward rectifier potassium channel Kir2.1

Márquez MF, et al. (2015). Síndrome de Andersen-Tawil : una revisión del diagnóstico genético y clínico con énfasis en sus manifestaciones cardíacas. Archivos de Cardiología de México, *84*(4), 278–285.

CLASSIFICATION

KCNJ2 mutations are detectable in only 60 % of patients with ATS

Until now no other mutations different from *KCNJ2 have been described.*

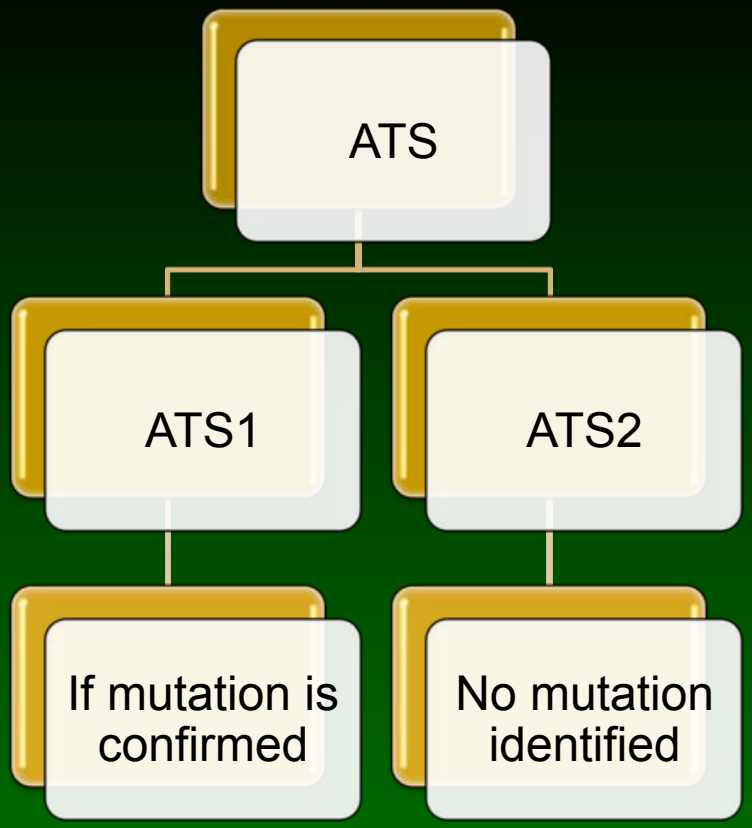

Márquez MF, et al. (2015). Síndrome de Andersen-Tawil : una revisión del diagnóstico genético y clínico con énfasis en sus manifestaciones cardíacas. Archivos de Cardiología de México, *84*(4), 278–285.

CLINICAL MANIFESTATIONS

Heart

- Arrhythmias
  - Ventricular extrasystoles
  - Ventricular tachycardia
  - NSVT,
  - AV block
  - RBBB, LBBB,
  - Bifascicular block, etc

Skeletal muscle

- Flaccid paralysis
- Impaired skeletal development (extremities and facial area).

Márquez MF, et al. (2015). Síndrome de Andersen-Tawil : una revisión del diagnóstico genético y clínico con énfasis en sus manifestaciones cardíacas. Archivos de Cardiología de México, *84*(4), 278–285.

CLINICAL MANIFESTATIONS

Physical characteristics

- Low-set ears, micrognathia, malar hypolasia
- Syndactyly, clinodactyly
- Short stature and scoliosis
- Elfin facies

Márquez MF et al. (2015). Abnormal electroencephalogram, epileptic seizures, structural congenital heart disease and aborted sudden cardiac death in Andersen–Tawil syndrome. *International Journal of Cardiology*, *180*, 206–209.

PART II

- 12-LEAD ECG FEATURES OF ATS

12-LEAD ECG FEATURES OF ATS

REPOLARIZATION ABNORMALITIES

- Prominent U-waves
- Q-U interval prolongation

CONDUCTION DISTURBANCES

- AV block
- RBBB or LBBB
- Bifascicular block

Márquez MF, et al. (2015). Síndrome de Andersen-Tawil : una revisión del diagnóstico genético y clínico con énfasis en sus manifestaciones cardíacas. Archivos de Cardiología de México, *84*(4), 278–285.

QT-U PROLONGATION

- **The real QT interval is normal if the U wave is excluded form the analysis**
- **The corrected Q-U interval is significantly longer**

A manifest U-wave is present in 90% of ATS1
Best seen in leads V2-V4 and in limb leads

Kukla P, et al (2014).
Electrocardiogram in Andersen-Tawil Syndrome . New Electrocardio- graphic Criteria for Diagnosis of Type-1 Andersen-Tawil Syndrome. Current Cardiology Reviews, 222–228.

PROLONGED Q-U INTERVAL (CORRECTED)

PVCs monomorphic

↓=U waves

QT -U (520 ms) at the expense of a U wave .

QU corrected (RR 720 ms) = 612

Márquez MF, et al. (2015). Síndrome de Andersen-Tawil : una revisión del diagnóstico genético y clínico con énfasis en sus manifestaciones cardíacas. Archivos de Cardiología de México, *84*(4), 278–285

PROLONGED TERMINAL T-WAVE

- Prolonged terminal T-wave downslope with biphasic U waves in limb leads and enlarged U waves in V2 and V3
- QTc 440 ms;
- QUc 660 ms

indicate prolonged terminal T-wave downslope

indicate biphasic U waves

Zhang et al.(2005). Electrocardiographic features in Andersen-Tawil syndrome patients with KCNJ2 mutations: Characteristic T-U-wave patterns predict the KCNJ2 genotype. *Circulation*, *111*(21), 2720–2726.

WIDE T-U JUNCTION

- QTc = 410 ms; QUc = 611 ms.
- PR interval (200 ms) - indicates 1st-degree AV block for age (<175 ms).
- Wide T-U junction characterizes ATS1 and differentiates it from the bifid T waves of LQT2.
- In leads V2 and V3, the enlarged U wave is greater than half of the T-wave amplitude,

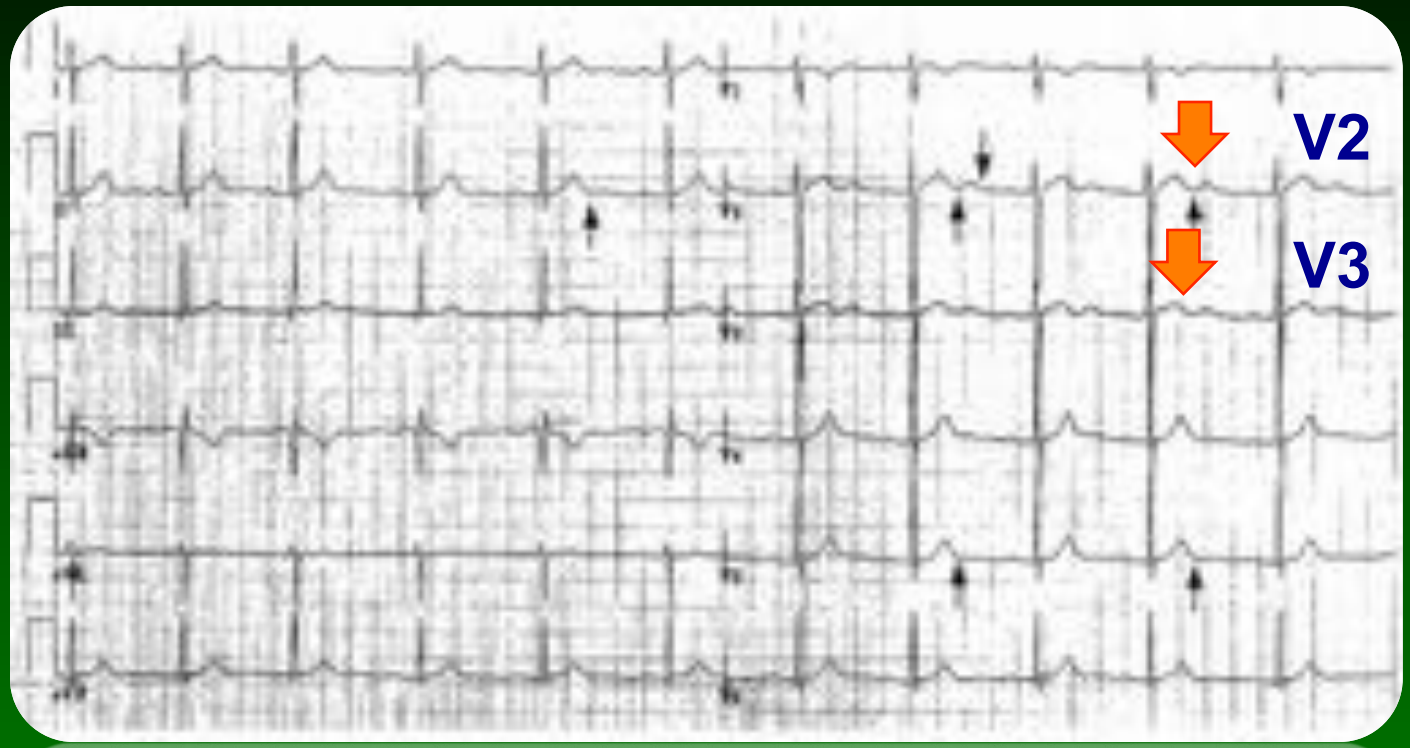

↑ indicate wide T-U junction

Zhang et al.(2005). Electrocardiographic features in Andersen-Tawil syndrome patients with KCNJ2 mutations: Characteristic T-U-wave patterns predict the KCNJ2 genotype. *Circulation*, *111*(21), 2720–2726.

ENLARGED U-WAVES

Frequent ventricular ectopy (arrow) and
prominent U waves (arrowhead)

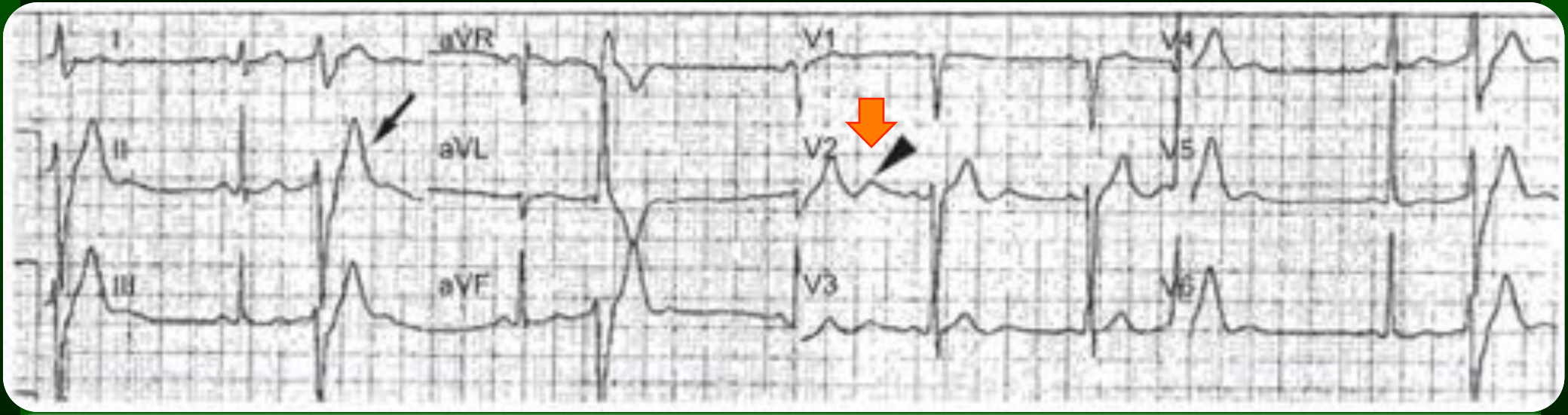

Marrus S, et al (2011).
Characterization of a novel, dominant negative KCNJ2 mutation associated with Andersen-Tawil syndrome. Channels, 5(6), 500–509

ENLARGED U-WAVES

RBBB and prominent U waves seen across the precordial leads

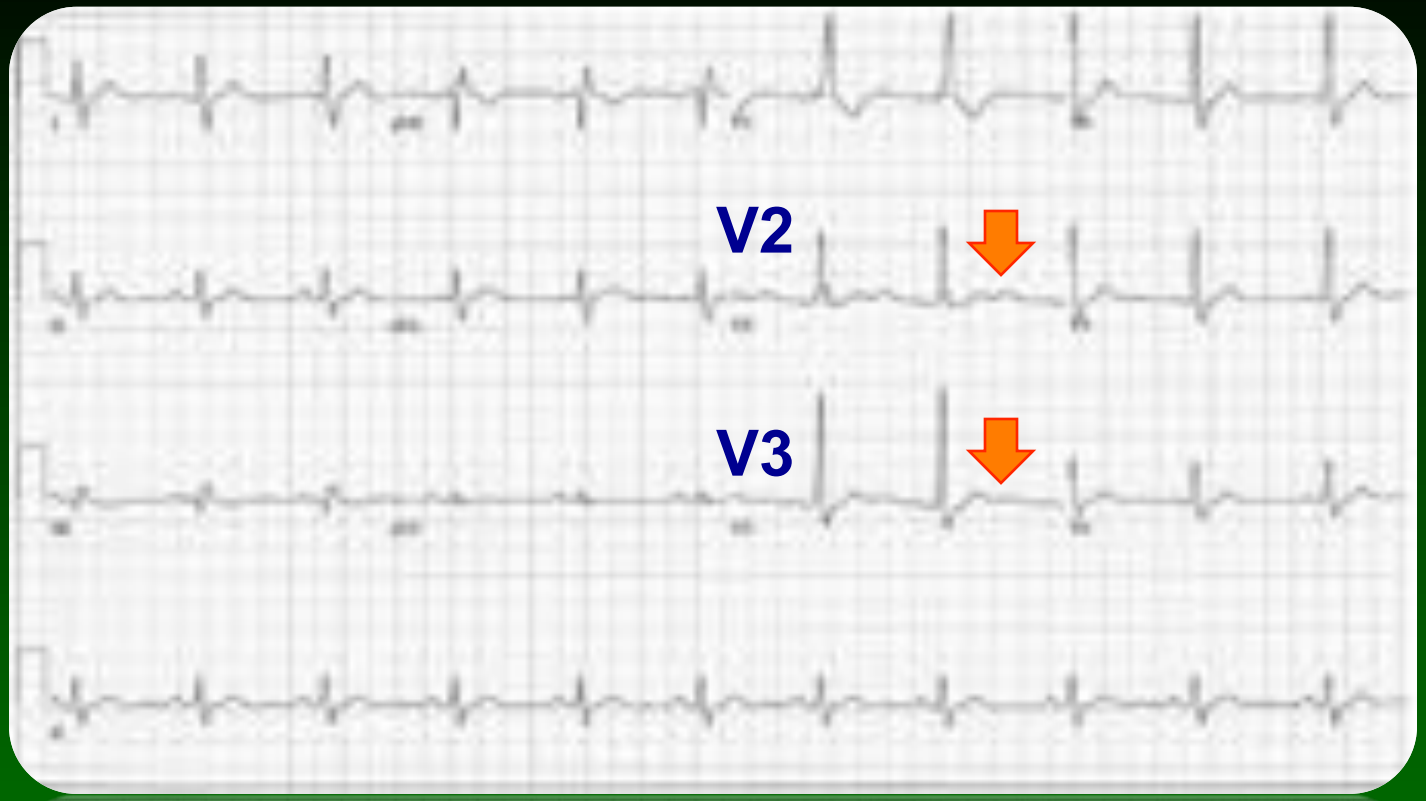

Fox David, et al . (2008).
Reduction of complex ventricular ectopy and improvement in exercise capacity with flecainide therapy in Andersen-Tawil syndrome. Europace, 10(8), 1006–1008.

ENLARGED U-WAVES

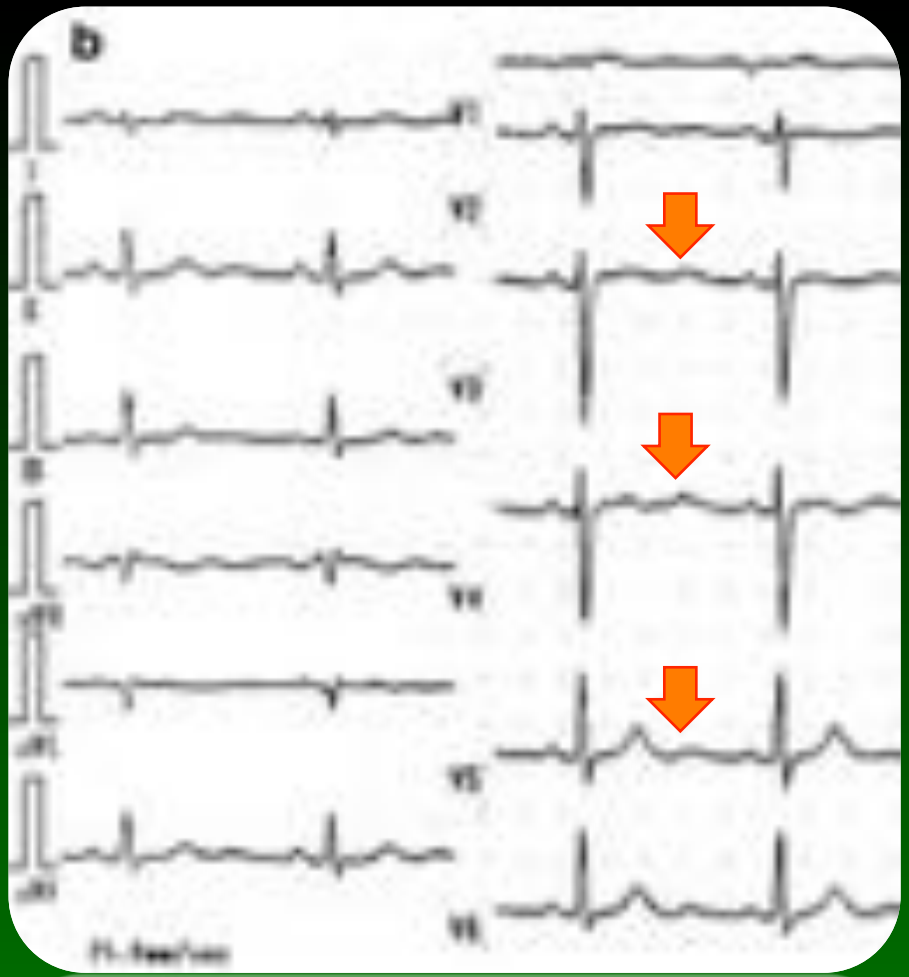

- QTc 440 ms
- Q-Uc prolongation
- Prominent U waves in leads V3 and V4.

Kuramoto, et al. (2012). Andersen-Tawil syndrome associated with aborted sudden cardiac death: atrial pacing was effective for ventricular arrhythmias. The American Journal of the Medical Sciences, 344(3), 248–50.

ABNORMAL T-U WAVES PATTERNS

"U on P" phenomenon

- **U wave masquerading P wave during sinus tachycardia – 83%**

🡻 "U on P" sign.

"U on P" sign (U-wave masquerading P-wave) the P-wave during sinus tachycardia is inscribed on the U-wave of the preceding beat

Kukla P, et al (2014). Electrocardiogram in Andersen-Tawil Syndrome . New Electrocardio- graphic Criteria for Diagnosis of Type-1 Andersen-Tawil Syndrome. Current Cardiology Reviews, 222–228.

ABNORMAL T-U WAVES PATTERNS

Pseudo “Tee-Pee” sign

- **A prolongation of the descending limb of the T+U wave during a PVC – 83%**

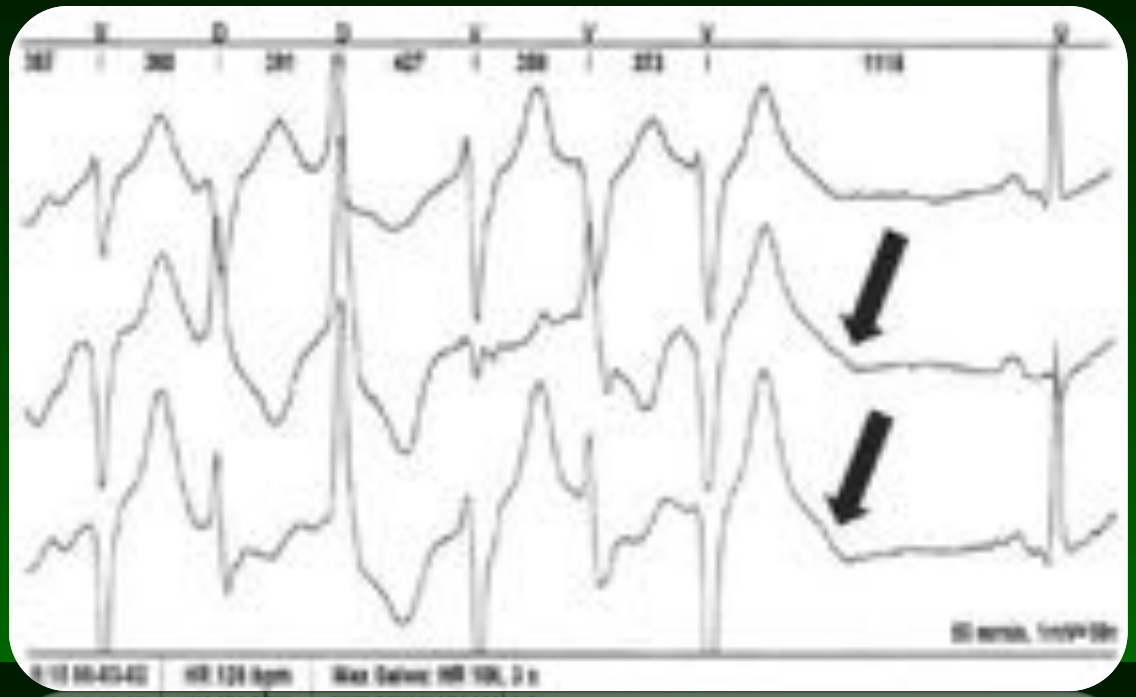

Pseudo “Tee - Pee sign”

Pseudo “Tee-pee sign” during a PVC, there is a prolongation of the descending limb of the T+U-wave..

Kukla P, et al (2014). Electrocardiogram in Andersen-Tawil Syndrome . New Electrocardio- graphic Criteria for Diagnosis of Type-1 Andersen-Tawil Syndrome. Current Cardiology Reviews, 222–228.

ABNORMAL T-U WAVES PATTERNS

Post-extrasystolic T+U fusion

- **Fusion of T and U waves in the sinus beat following a PVC – 83%**
- Pseudo–LQTS pattern

- Compare the distinction between T and U waves in sinus beats previous to the PVC with the T+U fusion in the sinus beat following the PVC

Kukla P, et al (2014). Electrocardiogram in Andersen-Tawil Syndrome . New Electrocardio- graphic Criteria for Diagnosis of Type-1 Andersen-Tawil Syndrome. Current Cardiology Reviews, 222–228.

ABNORMAL T-U WAVES PATTERNS

Adrenaline test

- **U-wave augmentation after adrenaline administration**

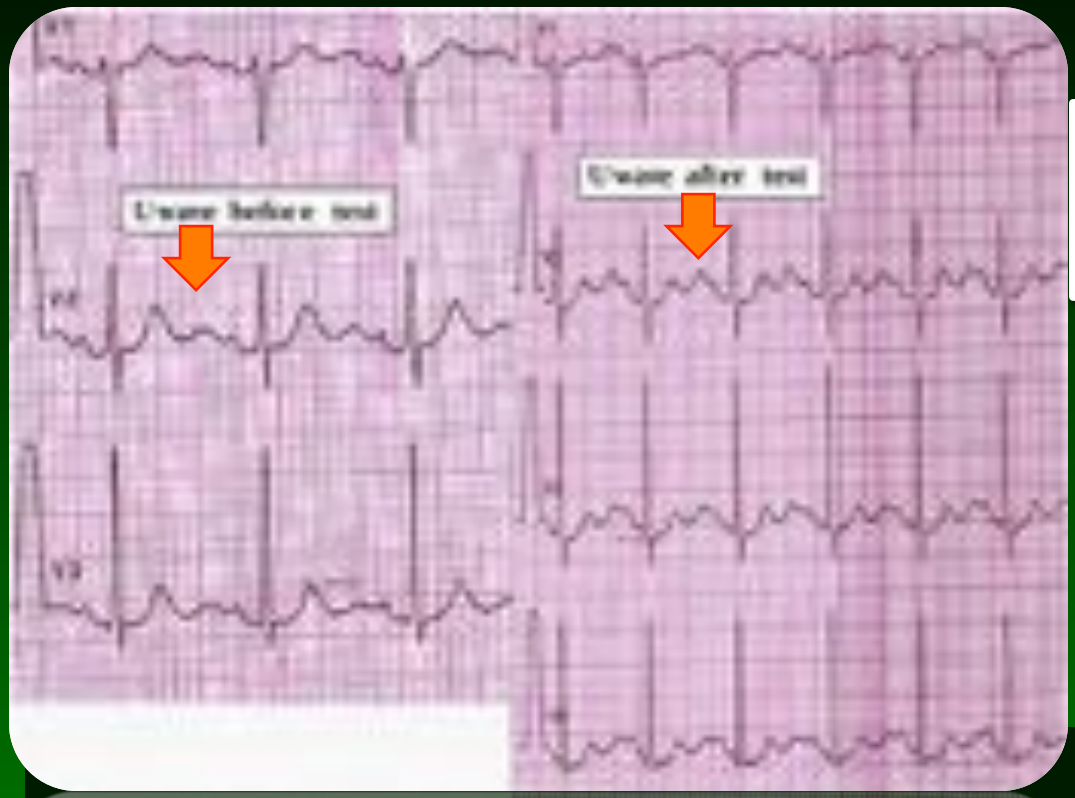

- The ratio amplitude of U-wave / T-wave becomes > 1 after adrenaline when compared to baseline ratio < 1

Kukla P, et al (2014). Electrocardiogram in Andersen-Tawil Syndrome . New Electrocardio- graphic Criteria for Diagnosis of Type-1 Andersen-Tawil Syndrome. Current Cardiology Reviews, 222–228.

CONDUCTION ABNORMALITIES

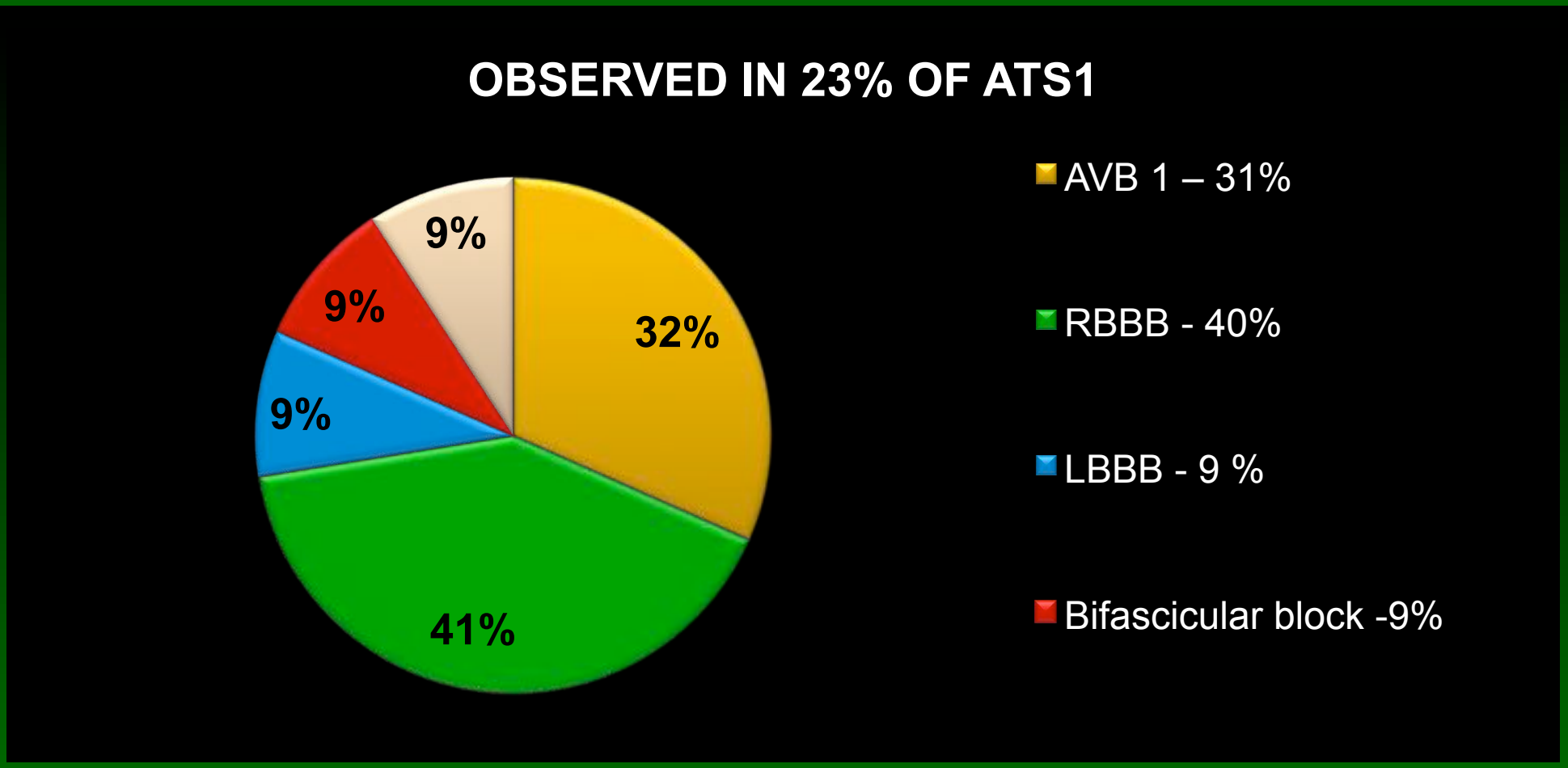

Zhang et al.(2005).
Electrocardiographic features in Andersen-Tawil syndrome patients with KCNJ2 mutations: Characteristic T-U-wave patterns predict the KCNJ2 genotype. *Circulation*, *111*(21), 2720–2726.

ABNORMAL T-U WAVE PATTERNS

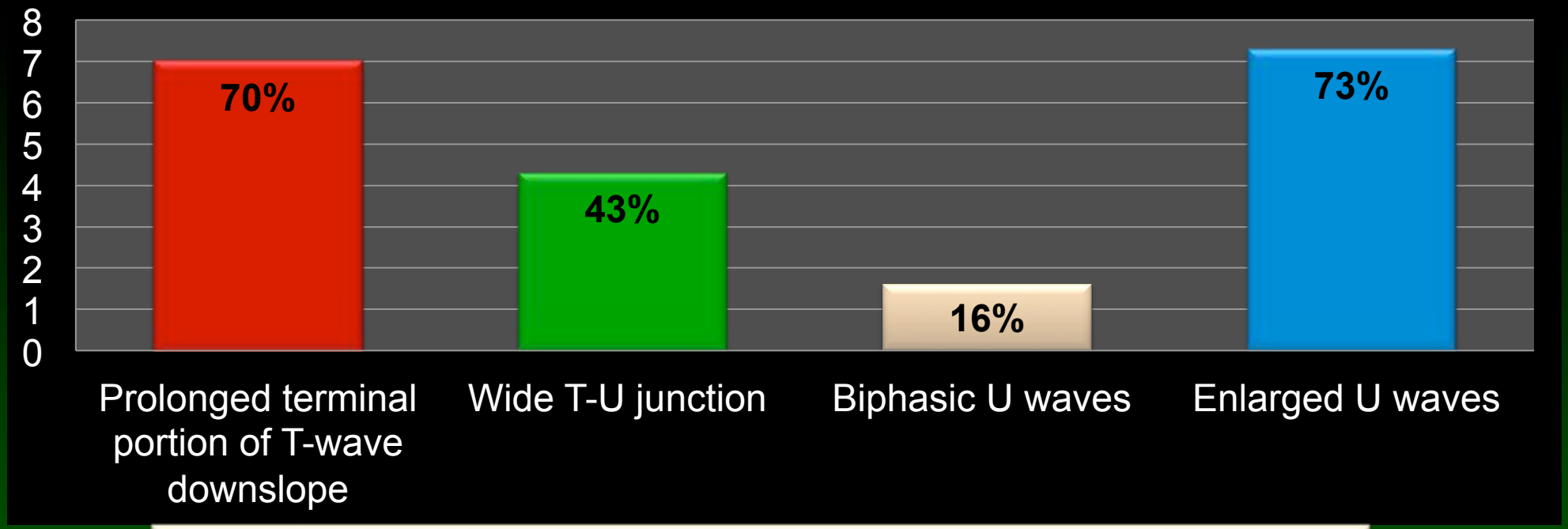

High predictive accuracy for ATS1 genotype prediction
(Zhang, 2005):
94% Positive predictive value
91% Negative predictive value

Zhang et al.(2005).
Electrocardiographic features in Andersen-Tawil syndrome patients with KCNJ2 mutations: Characteristic T-U-wave patterns predict the KCNJ2 genotype. *Circulation*, *111*(21), 2720–2726.

PART III

VENTRICULAR ARRHYTHMIAS IN ATS

VENTRICULAR ARRHYTHMIAS IN ATS

Ventricular extrasystoles – 41%

- Ventricular bigeminy – 59%

Ventricular tachycardia – 23%

- Bidirectional tachycardia – 68%
- Polymorphic tachycardia – 29%
- Torsades de pointes – 3%

Zhang et al.(2005).
Electrocardiographic features in Andersen-Tawil syndrome patients with KCNJ2 mutations: Characteristic T-U-wave patterns predict the KCNJ2 genotype. *Circulation*, *111*(21), 2720–2726.

12-LEAD ECG: BIGEMINY

Márquez FM, Pellizon O, Iturralde I.
Síndrome de Andersen-Tawil. Revista CONAREC, 2015 (in press).

HOLTER MONITORING:TRIGEMINY

BIGEMINY & NSVT

- Frequent PVCs in bigeminy
- NSVT=Bidirectional VT (most evident in lead II and V3).

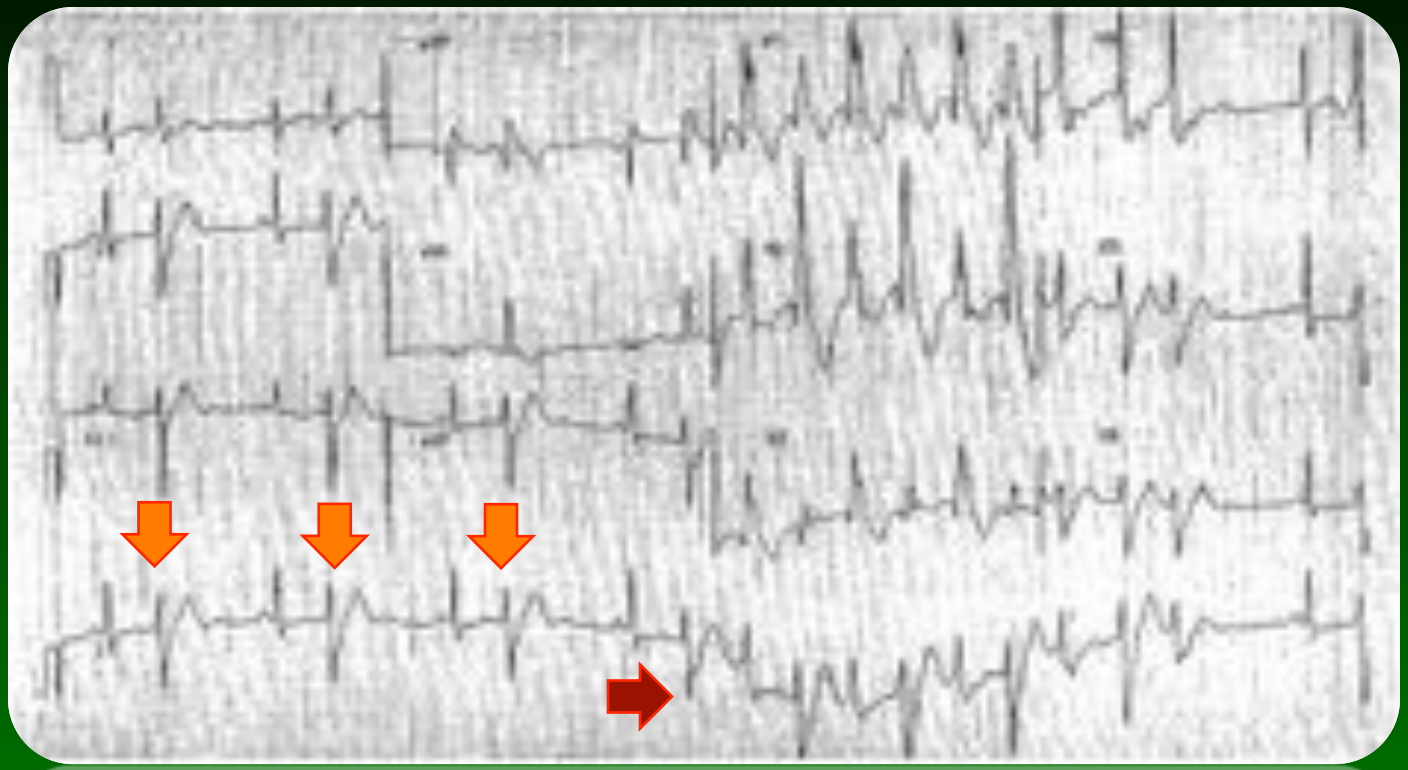

Zhang et al.(2005).
Electrocardiographic features in Andersen-Tawil syndrome patients with KCNJ2 mutations: Characteristic T-U-wave patterns predict the KCNJ2 genotype. *Circulation*, *111*(21), 2720–2726.

BIDIRECTIONAL VENTRICULAR TACHYCARDIA

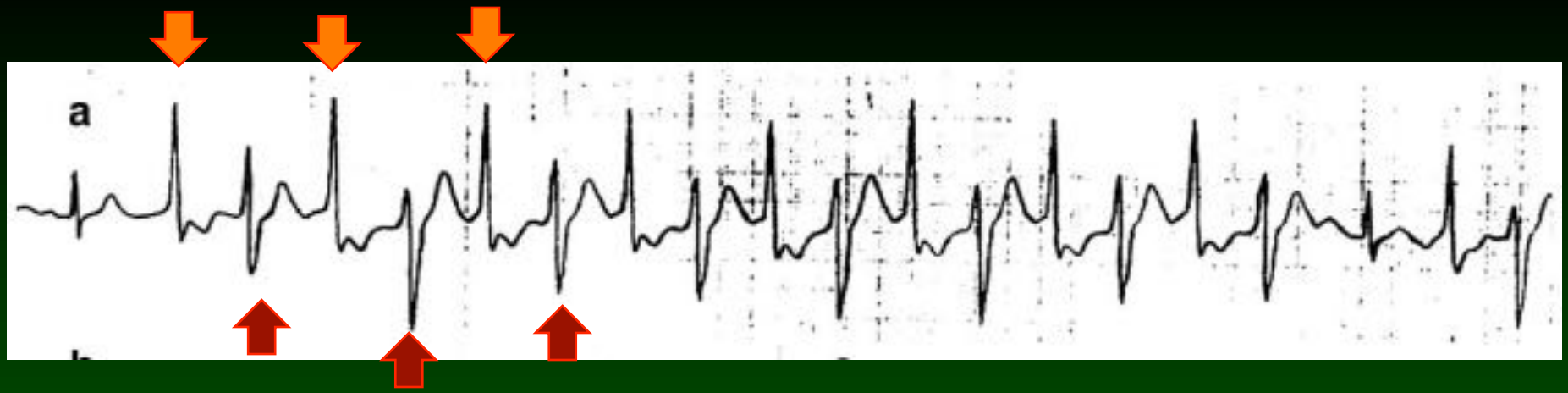

Bidirectional ventricular tachycardia

Kuramoto, et al. (2012). Andersen-Tawil syndrome associated with aborted sudden cardiac death: atrial pacing was effective for ventricular arrhythmias. The American Journal of the Medical Sciences, 344(3), 248–50.

BIGEMINY WITH NONSUSTAINED VT IN HOLTER

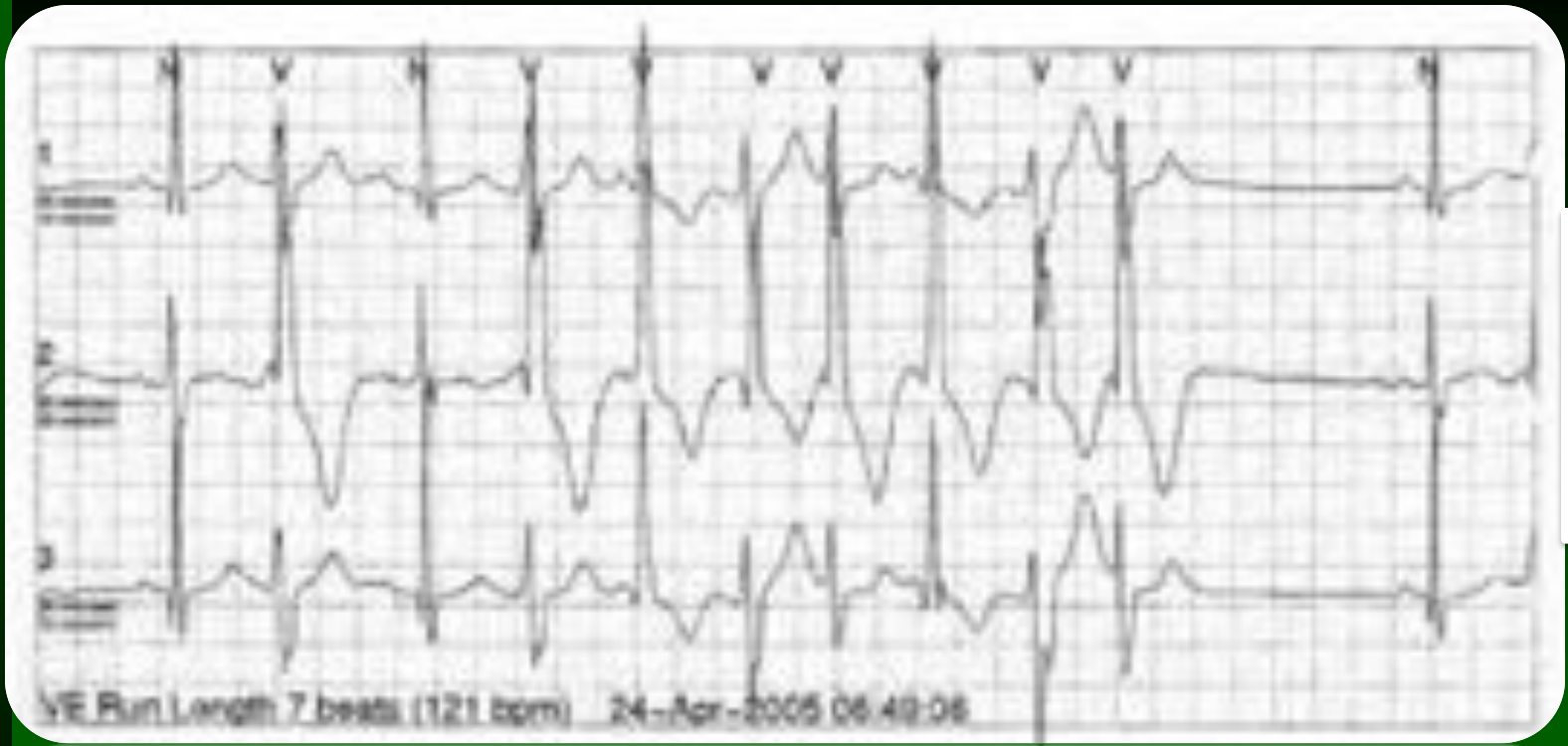

Holter monitor recording demonstrating bigeminy with nonsustained VT

Airey, K, et al. (2009). Resuscitated sudden cardiac death in Andersen-Tawil syndrome. Heart Rhythm : The Official Journal of the Heart Rhythm Society, 6(12), 1814–7.

BIGEMINY WITH NONSUSTAINED VT IN HOLTER

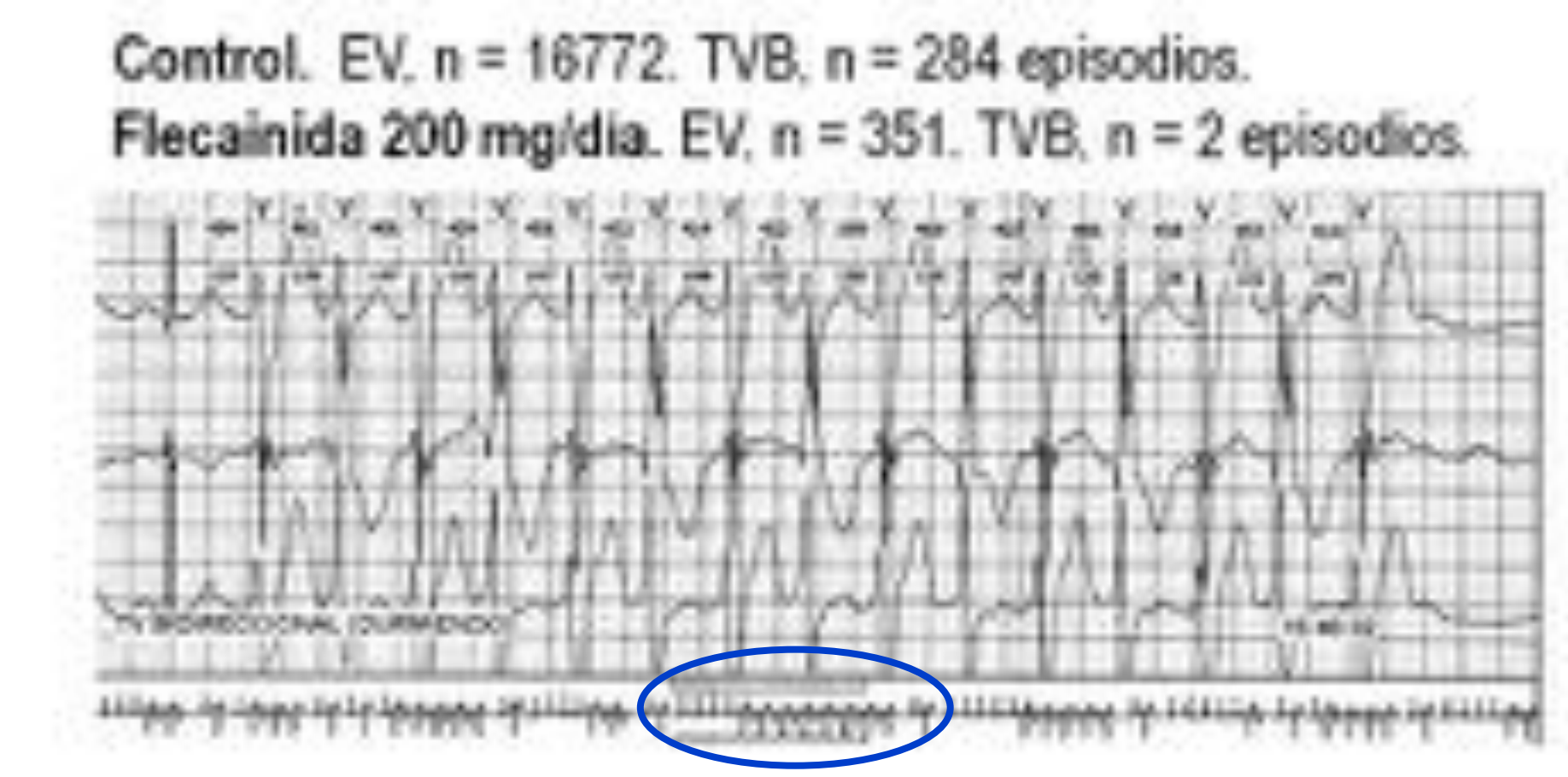

Márquez FM, Pellizon O, Iturralde I.
Síndrome de Andersen-Tawil. Revista CONAREC, 2015 (in press).

BIGEMINY WITH NONSUSTAINED VT IN HOLTER

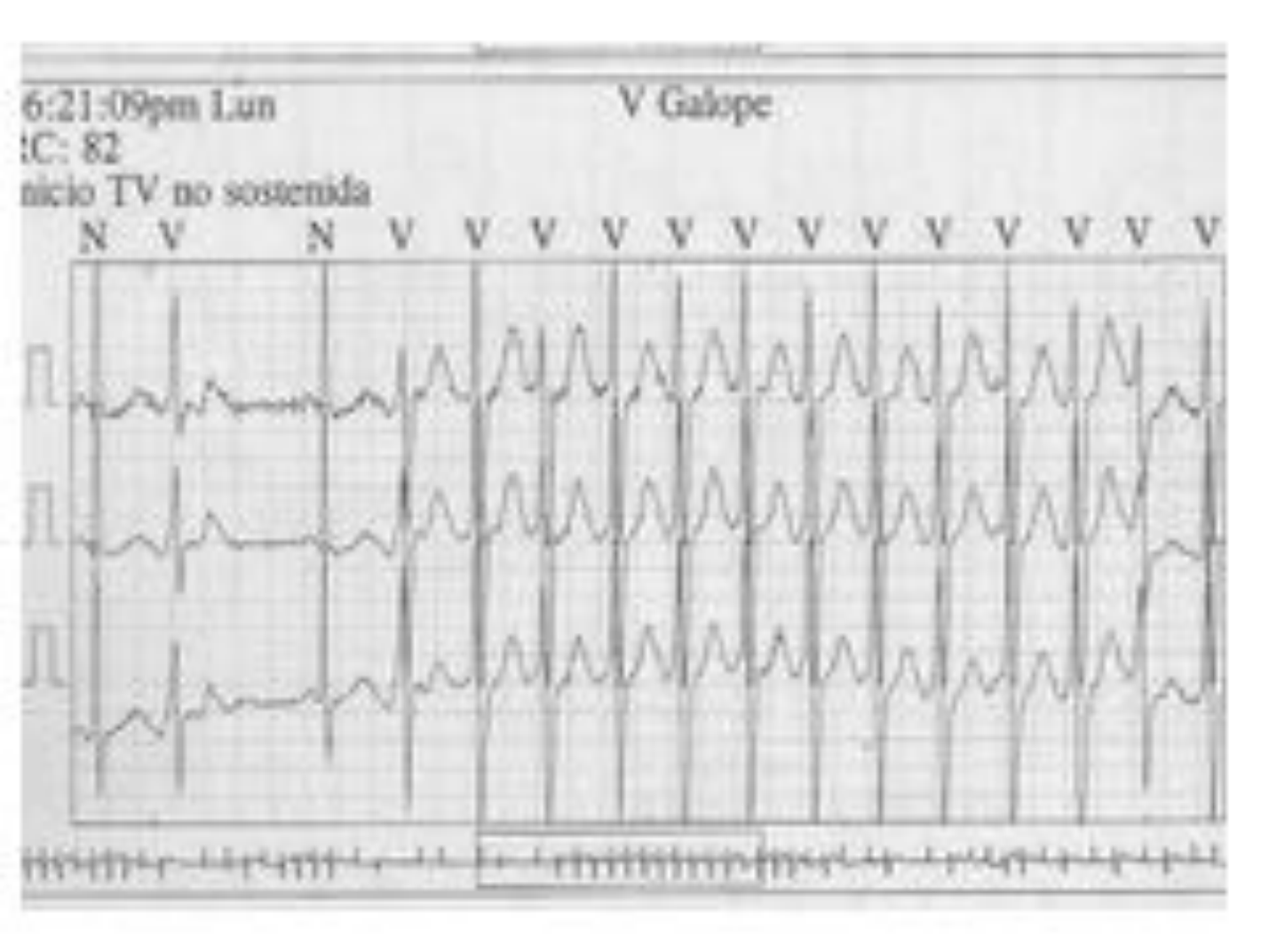

Holter monitor with monomorphic nonsustained VT

POLYMORPHIC VT

Loop recorder rhythm strip:
Bigeminy followed by polymorphic VT, alternating with monomorphic VT, deteriorating into asystole.

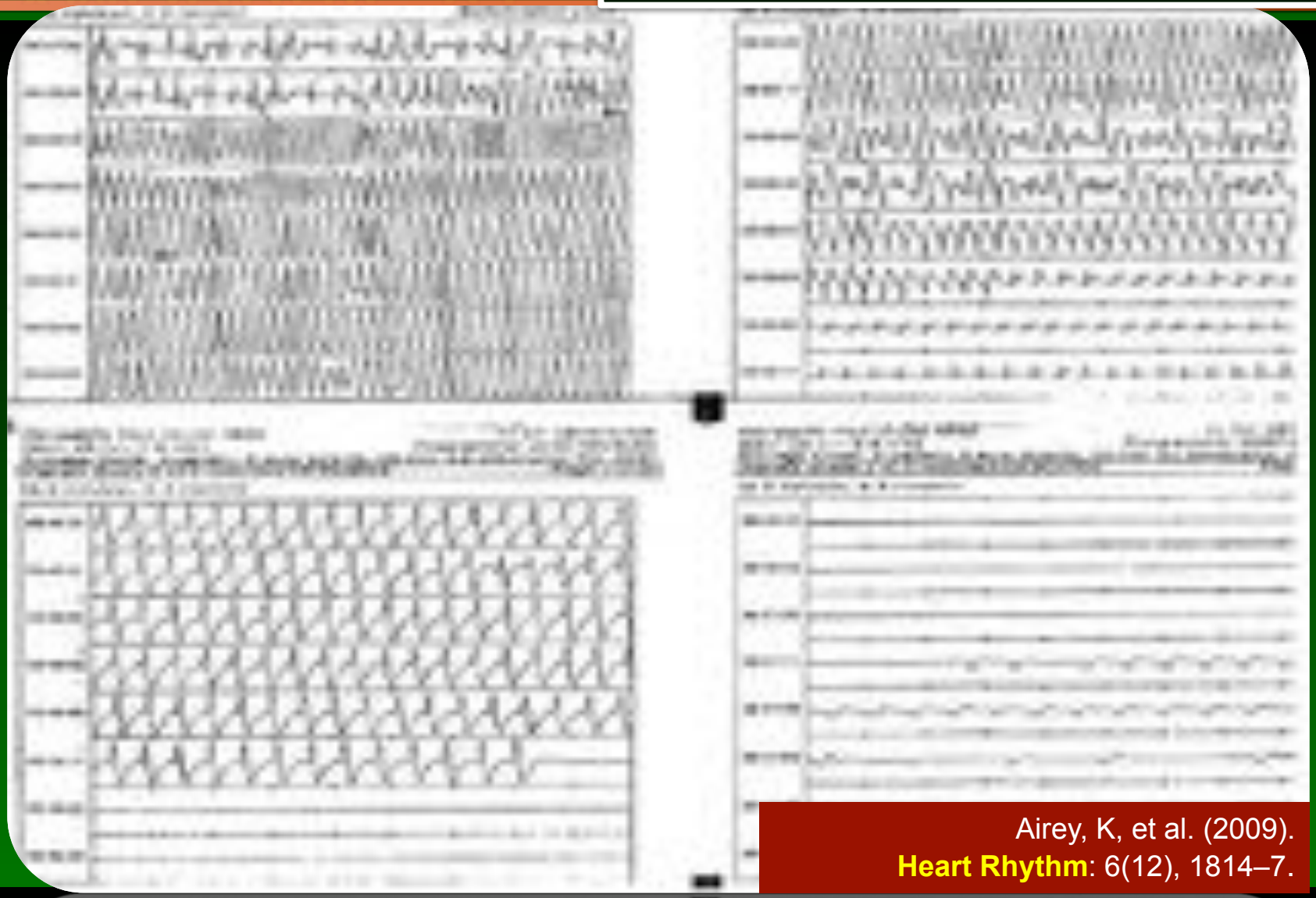

Airey, K, et al. (2009).
Heart Rhythm: 6(12), 1814–7.

Indian PACING and ELECTROPHYSIOLOGY Journal www.ipej.org

MEXICO
INSTITVTO·N·DE CARDIOLOGIA IGNACIO·CHAVEZ

Review Article

Andersen-Tawil Syndrome

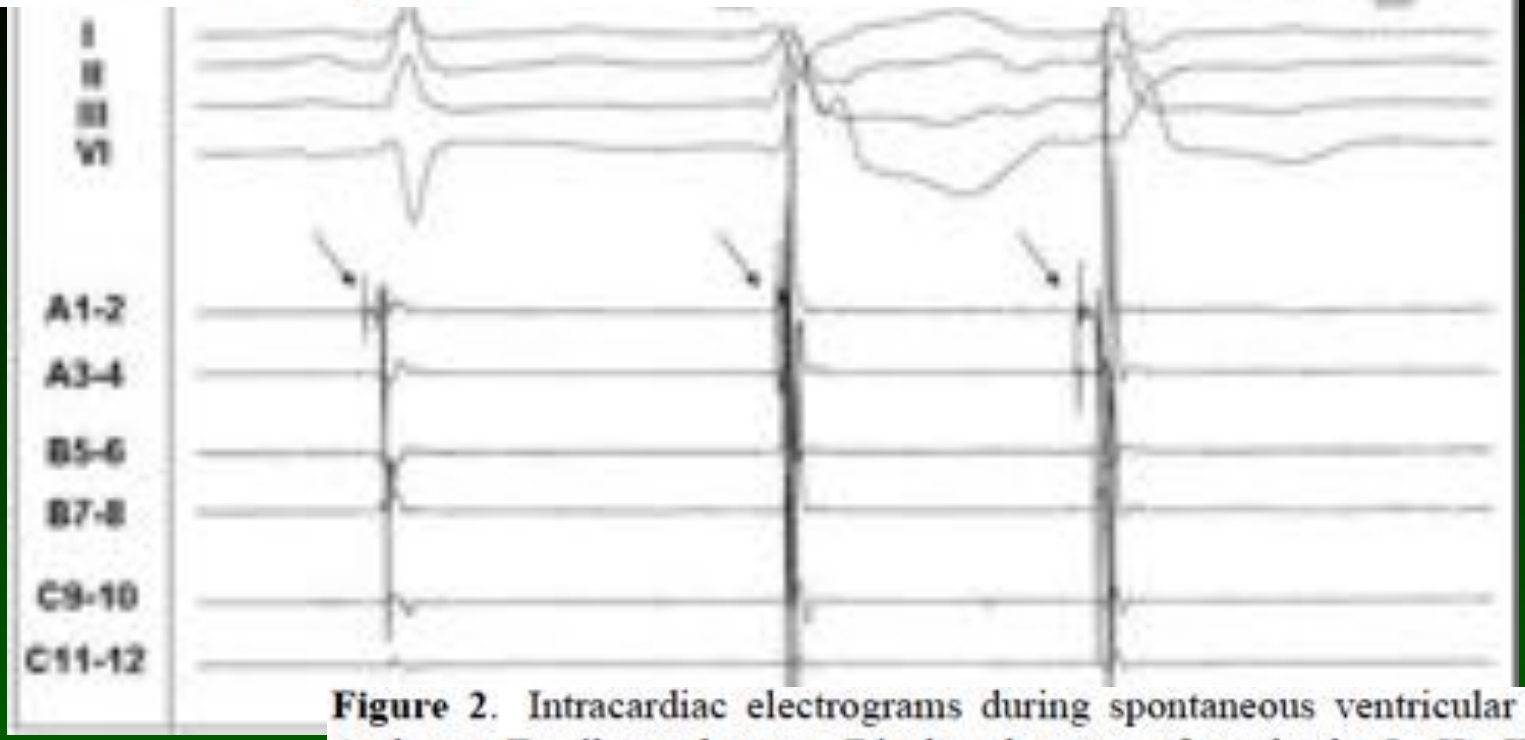

Figure 2. Intracardiac electrograms during spontaneous ventricular ectopy in a patient with Andersen-Tawil syndrome. Displayed are surface leads I, II, III, V1, and intracardiac electrograms recorded from the anterior left ventricle. The first sinus beat is followed by 2 successive ventricular ectopic beats, each with a different morphology. The arrows indicate Purkinje potentials preceding the local ventricular electrograms in sinus rhythm and the ectopic beats. The first ectopic beat is from an adjacent Purkinje site – hence the late Purkinje relative to the QRS. (Figure courtesy of Dr. Prashanthan Sanders, Dr. Frederic Sacher, and Dr. Michel Haissaguerre, Hôpital Cardiologique du Haut-Lévêque, Bordeaux, France)

Conclusions

- ATS has a characteristic ECG phenotype
  - ✓ Increased U waves are the hallmark of the disease
- Ventricular arrhtyhmias are frequent
  - ✓ PVCs in bigeminy are the most common finding
  - ✓ Ventricular tachyarrhythmias can also be present
- ATS is increasingly recognized as a cause of SCD