VENICE ARRHYTHMIAS, 16-18 OCTOBER, 2015

NONINVASIVE ECG IMAGING VISUALISES ROTORS AND MULTIPLE WAVELETS IN PATIENTS WITH VENTRICULAR FIBRILLATION

E. Fetisova[1], A. Tsyganov [1], E. Wissner[2], M. Chaykovskaya [1], M. Chmelevsky[1], S. Deiss[2], T. Maurer[2], M. Yakovleva[1], K.H. Kuck[2]

[1]Petrovsky Research Surgery Centre, Moscow, Russia

[2]Asklepios Klinik St. Georg, Hamburg, Germany

DISCLOSURE

I have nothing to declare

What is Noninvasive ECG Imaging?

Noninvasive ECGI is the technology of numerical reconstruction and visualization of the electrical heart activity based on the ECG data measured on the body surface

MRI or CT scan

ECG registration

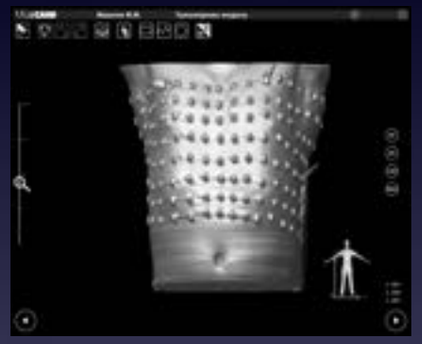

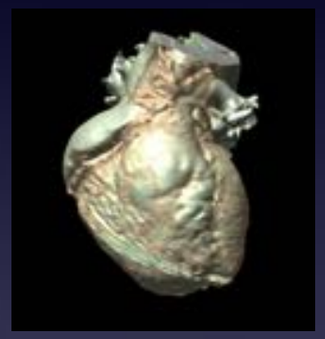

TORSO AND HEART VOLUME RECONSTRUCTION

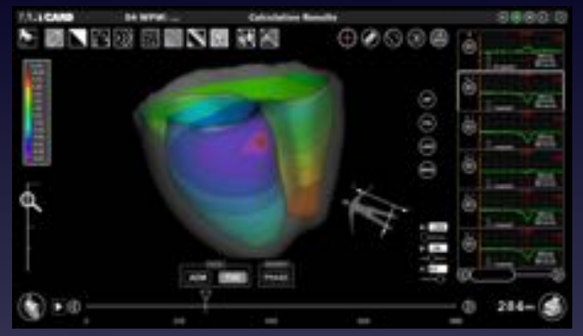

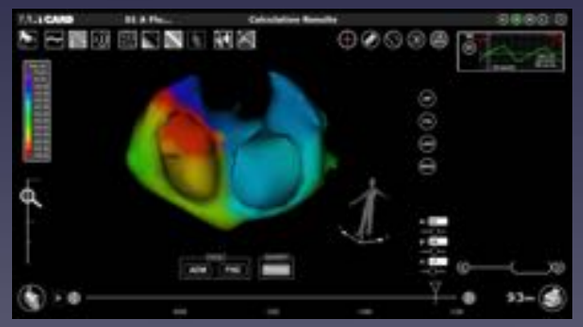

VOLTAGE, ISOCHRONE AND PHASE MAPS OF EPICARD AND ENDOCARD

Phase mapping

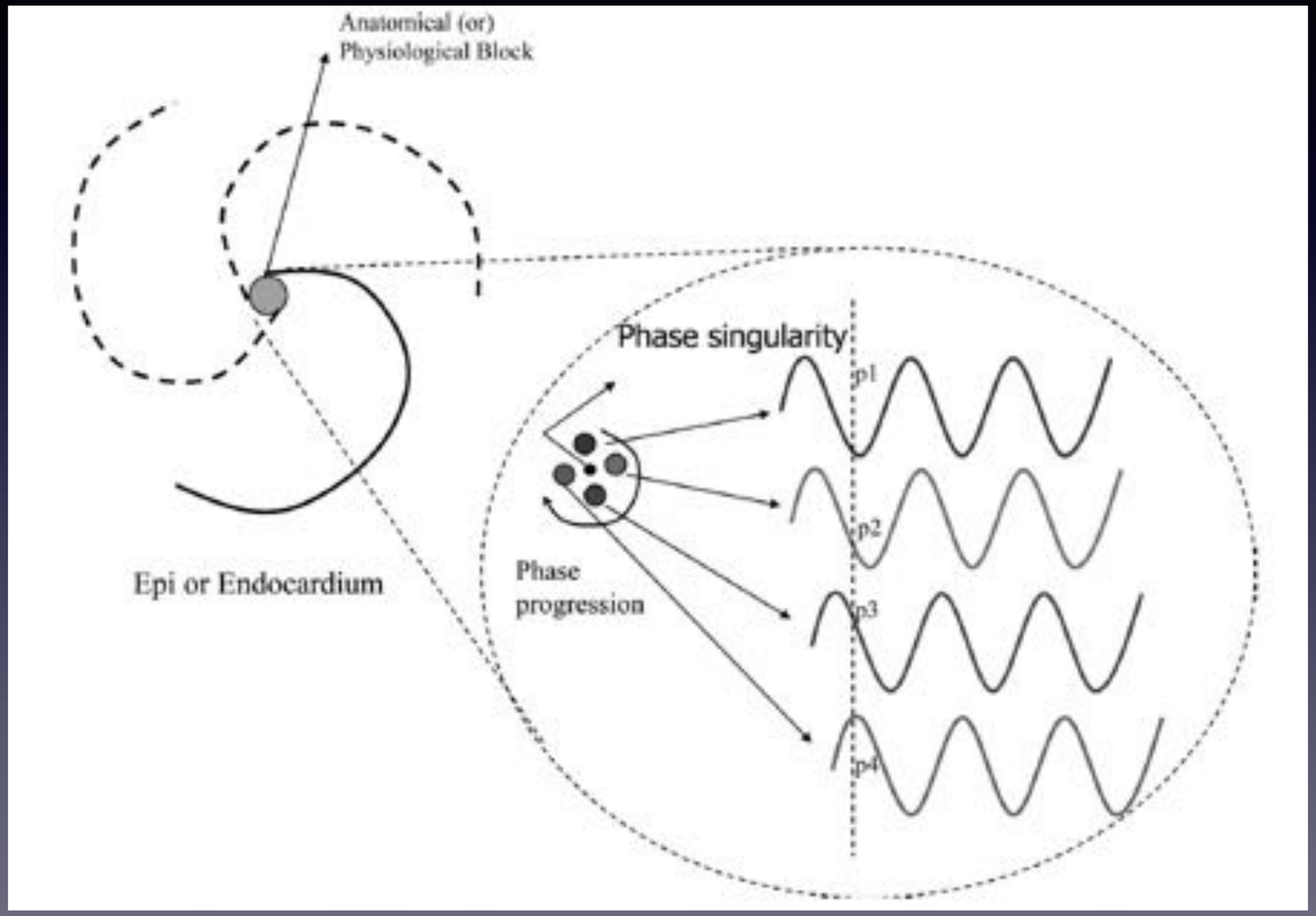

Phase Mapping of Cardiac Fibrillation K Umapathy et al. Circ Arrhythm Electrophysiol. 2010; 3:105-14

Objectives

To obtain the mechanism of maintenance the VF/VT in human heart (in vivo)

To find the substrate target for VF/VT ablation

Patient Characteristics

N	Ds	Episodes	TCL	Rot	Loc	Duration, s
Pat N1, 51 m	ICM	MMVT	300	1	Endo	6
Pat N2, 54 m	Sarcoidosis	PMVT	210	3	Epi	18
Pat N3, 28 m	HCM	PMVT	200	2	Endo	5
Pat N4, 38 f	BrS	PMVT	160	3	Epi	17
Pat N5, 60 m	ICM	MMVT	450	1	Endo	25
Pat N6, 79 m	ICM	MMVT	460	1	Endo	Incessant
Pat N7, 58 m	Idiopathic	VF	160	2	Epi	10
Pat N8, 31 m	BrS	VF	160	3	Epi	20

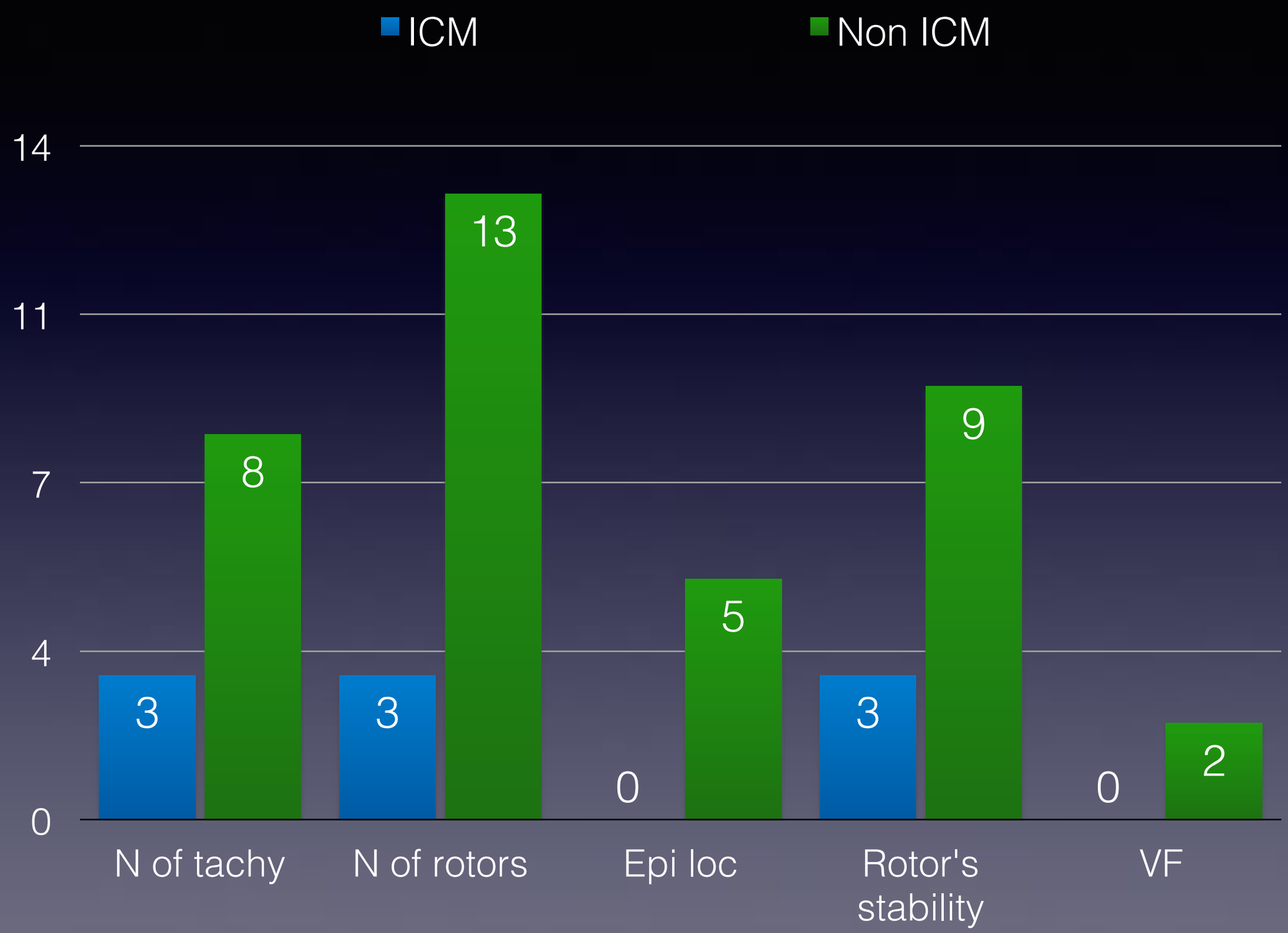
ICM
Non ICM
14
11
7
4
0
3
8
3
13
0
5
3
9
0
2
N of tachy
N of rotors
Epi loc
Rotor's stability
VF

Rotors' activity characteristic

N	Diagnosis	Episode duration	Dominant frequency	Rotor's location	Rotor's stability, cycle			Rotor's life expectancy		
					Min	Max	Mean	1 pair of rotors	2 pairs of rotors	3 pairs of rotors
1	BrS	17 s	5.6 Hz	RV apex, LV lateral wall, RV lateral wall	2	11	3.4	5 s (33%)	8 s (53%)	3 s (20%)
2	BrS	20 s	5.2 Hz	LV lateral wall, postero-septal area, RVOT lateral wall	1	5	1.8	-	7 s (35%)	13 s (65%)
3	HCM	5 s	4.9 Hz	RVOT postero-septal, MA lateral wall	1	4	4.0	3.5 s (70%)	1.5 s (30%)	-
4	Idiopathic	10 s	4.8 Hz	LV apex, RVOT postero-lateral, MA antero-septal	2	12	6.3	6.5 s (65%)	3.5 s (35%)	-

CASE N 1

79 y.o. male, past MI, CABG, PCI, incessant VT, EF 50%

CASE N 1

NONINVASIVE / CARTO VOLTAGE MAP

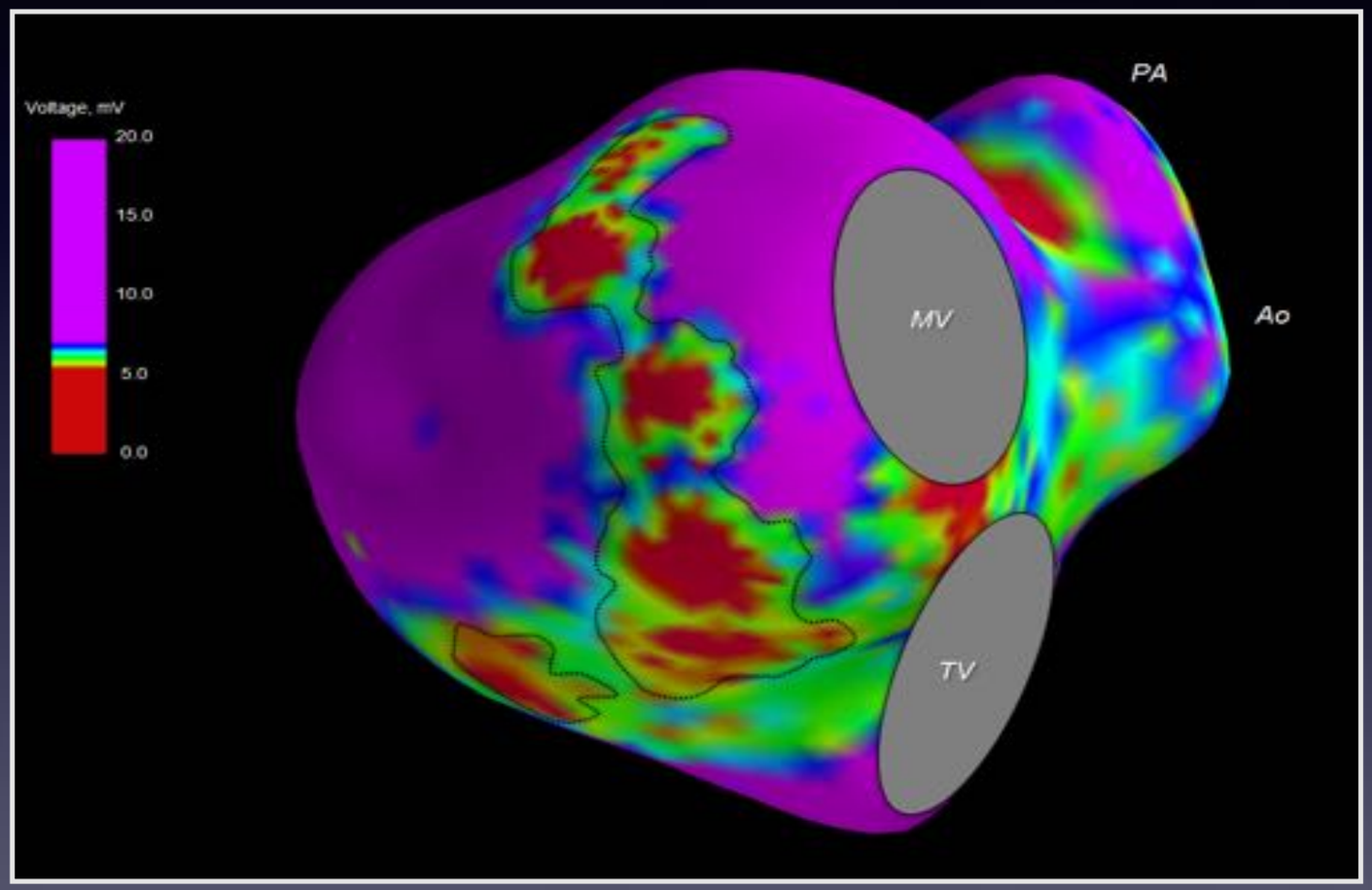

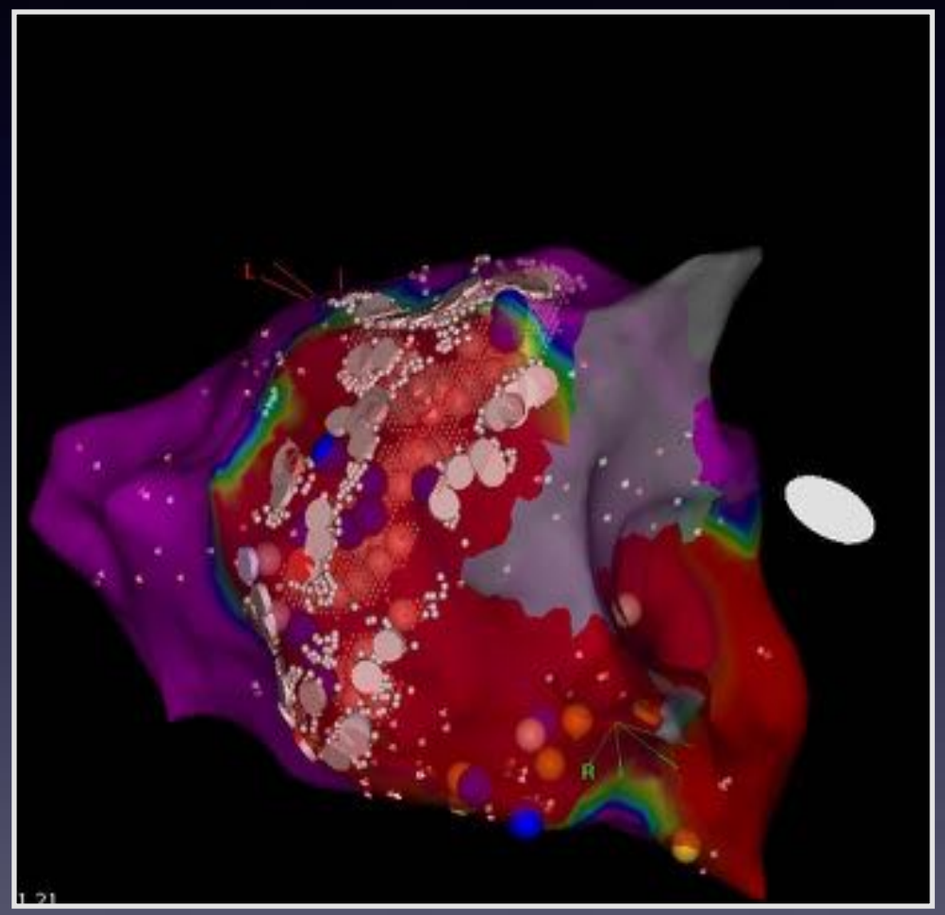

CASE N 1

CARTO / EP Solutions PROPAGATION MAPS

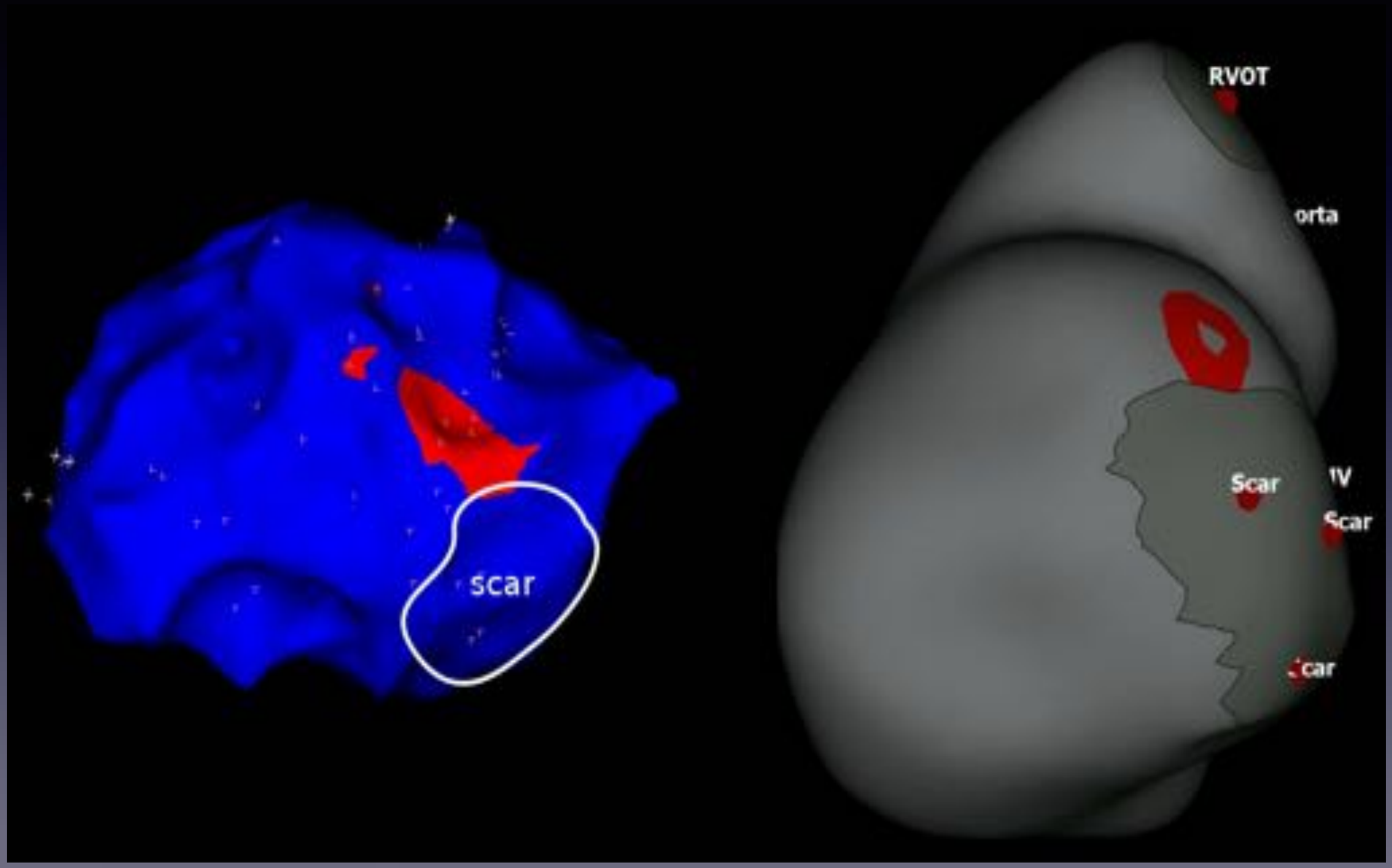

CASE N 1 Phase map

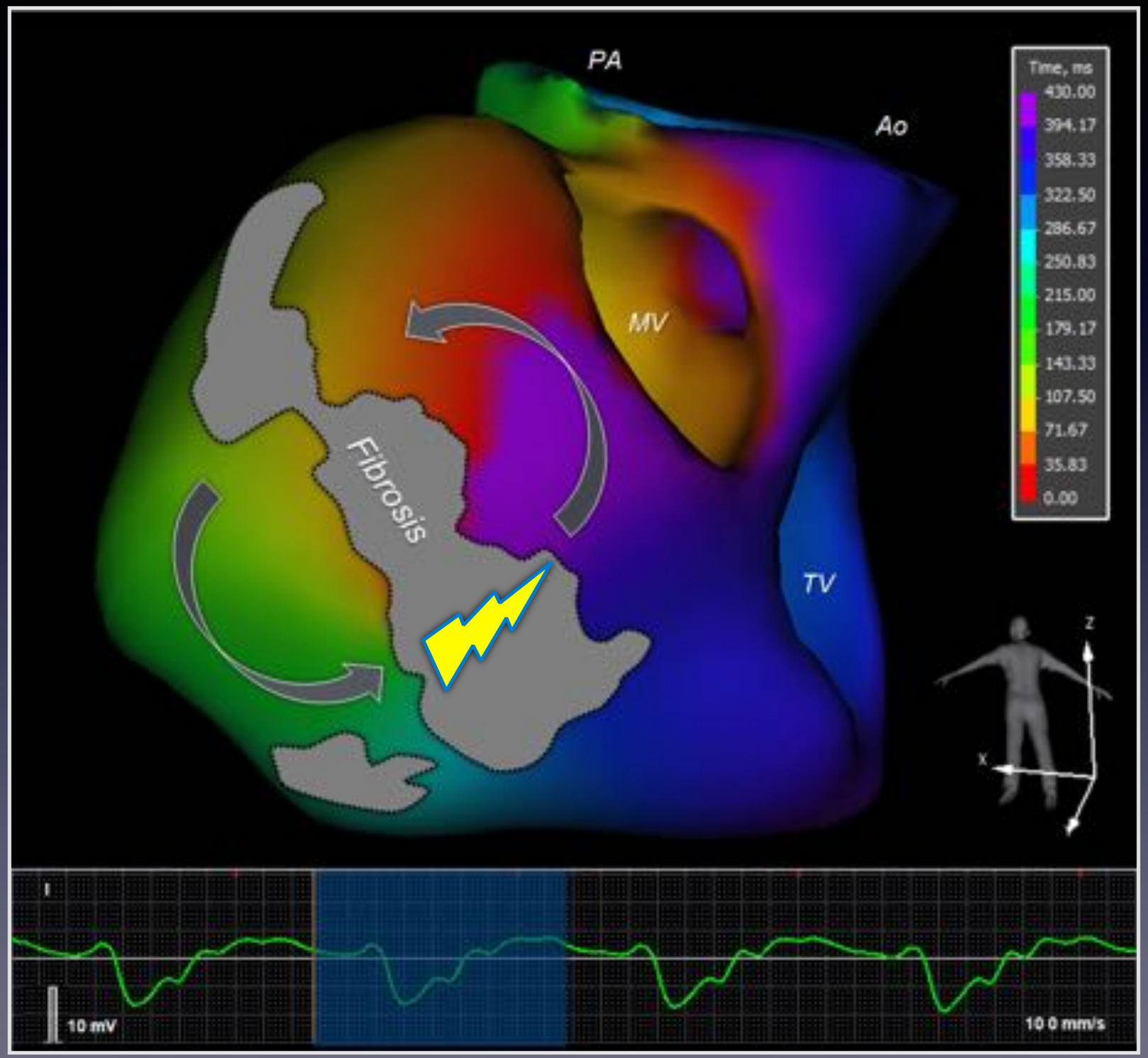

CASE N 1

CARTO / EP Solutions PROPAGATION MAPS

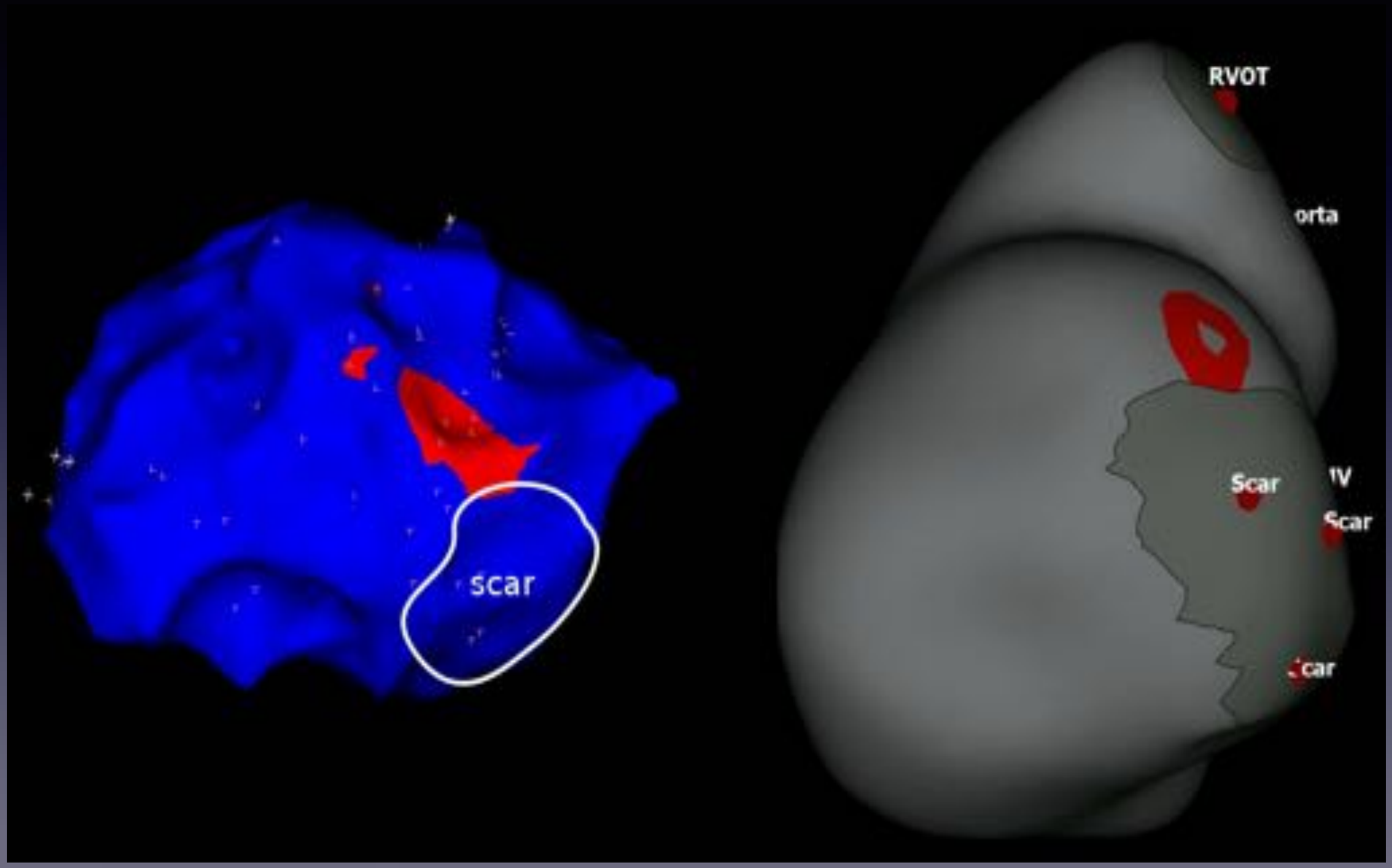

CASE N 2

54 y.o. male, Non-sustained VT, Syncope, EF 50%
Transthoracic needle biopsy - Sarcoidosis
MRI scars: IVS, RVOT, mid postero-lateral LV (Epi)

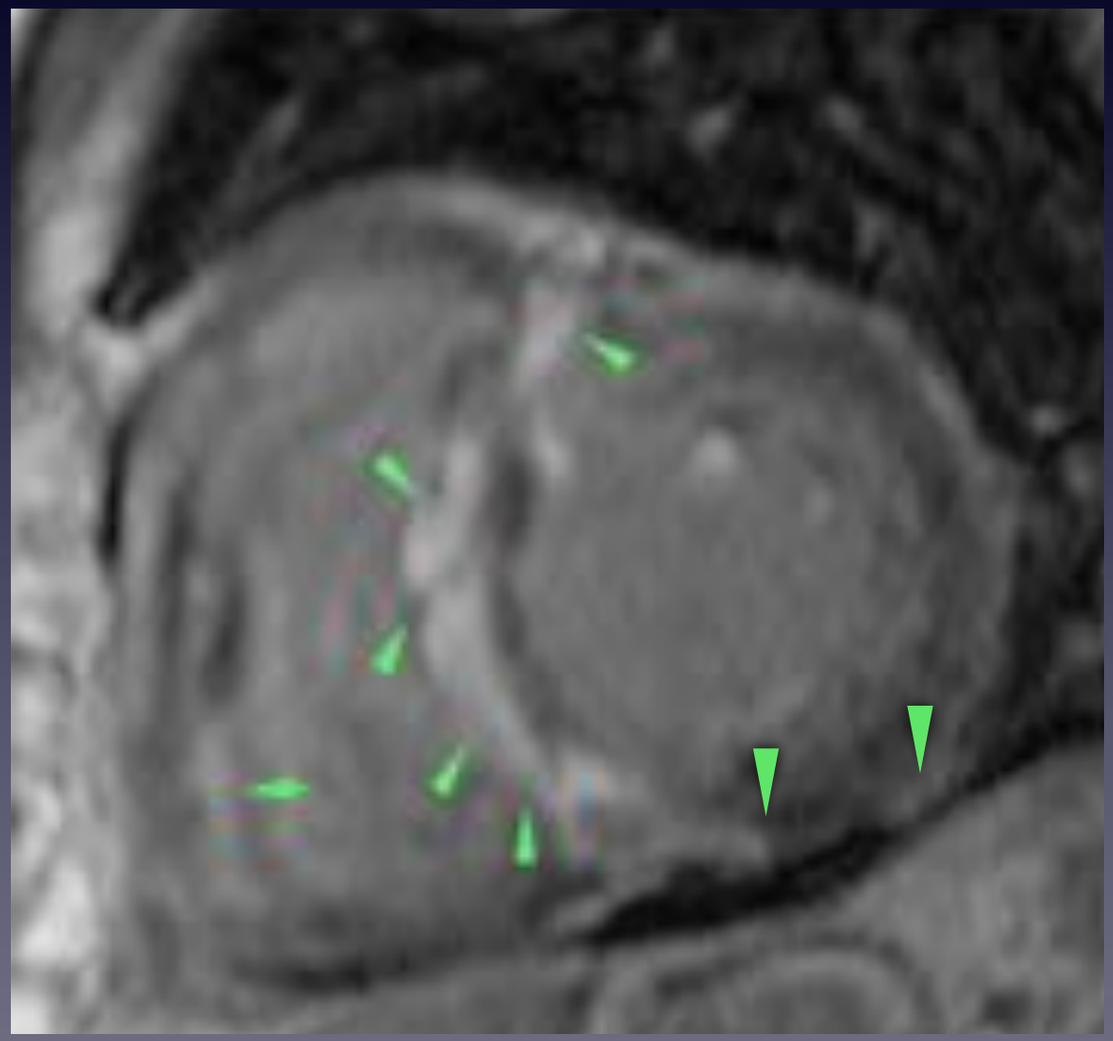

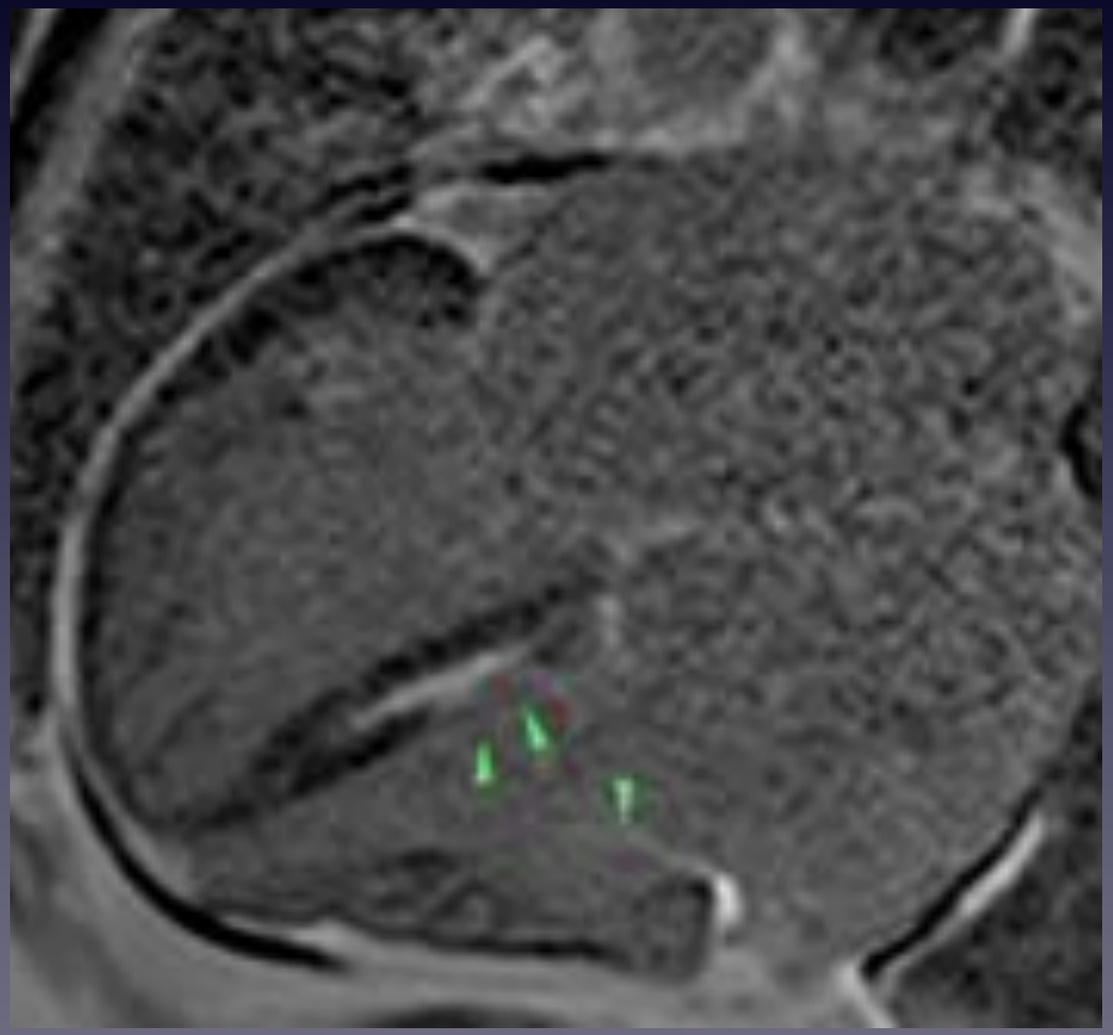

CASE N 2 ECG

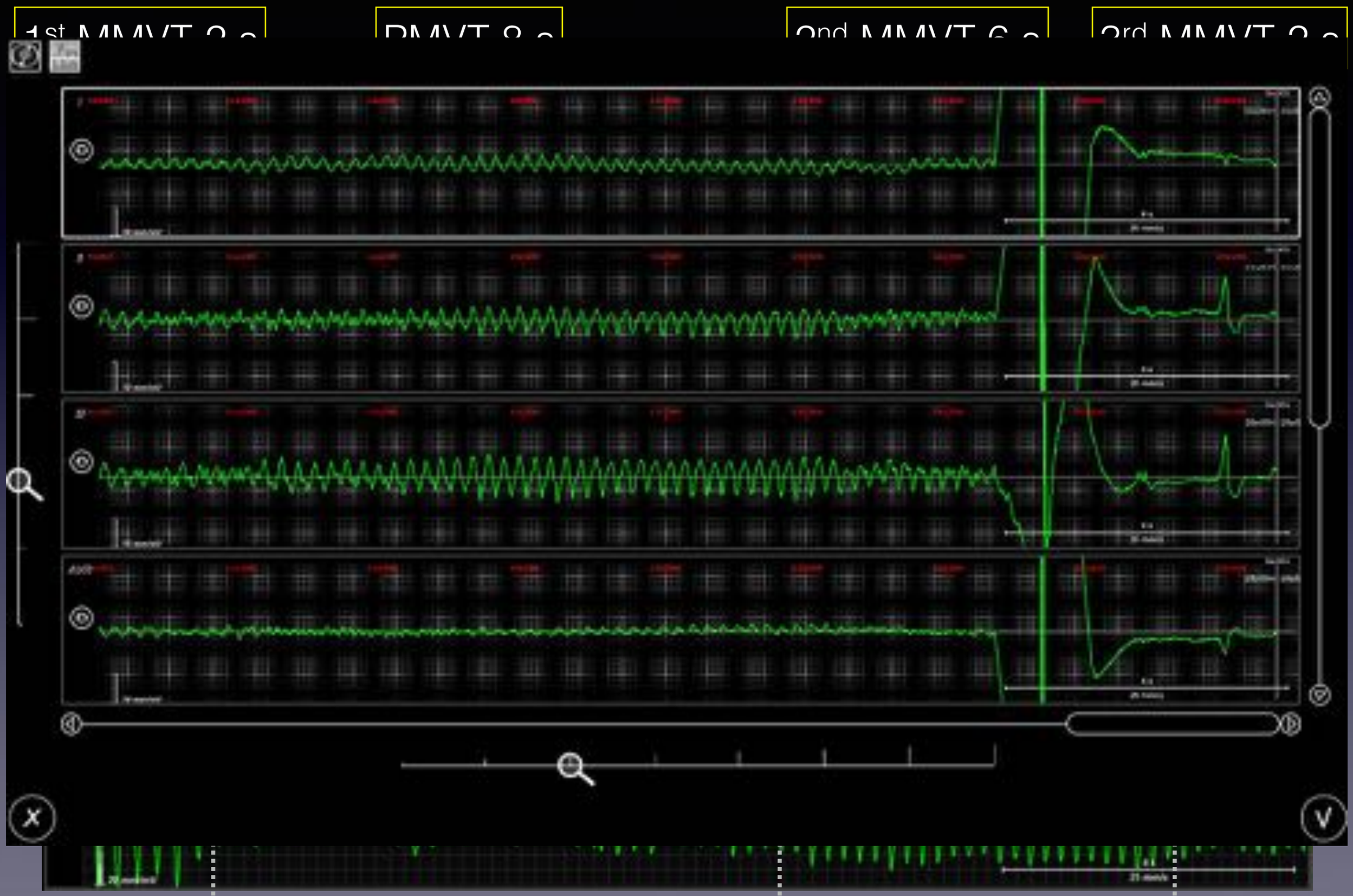

CASE N 2 ECG

1st MMVT 2 s | PMVT 8 s | 2nd MMVT 6 s | 3rd MMVT 2 s

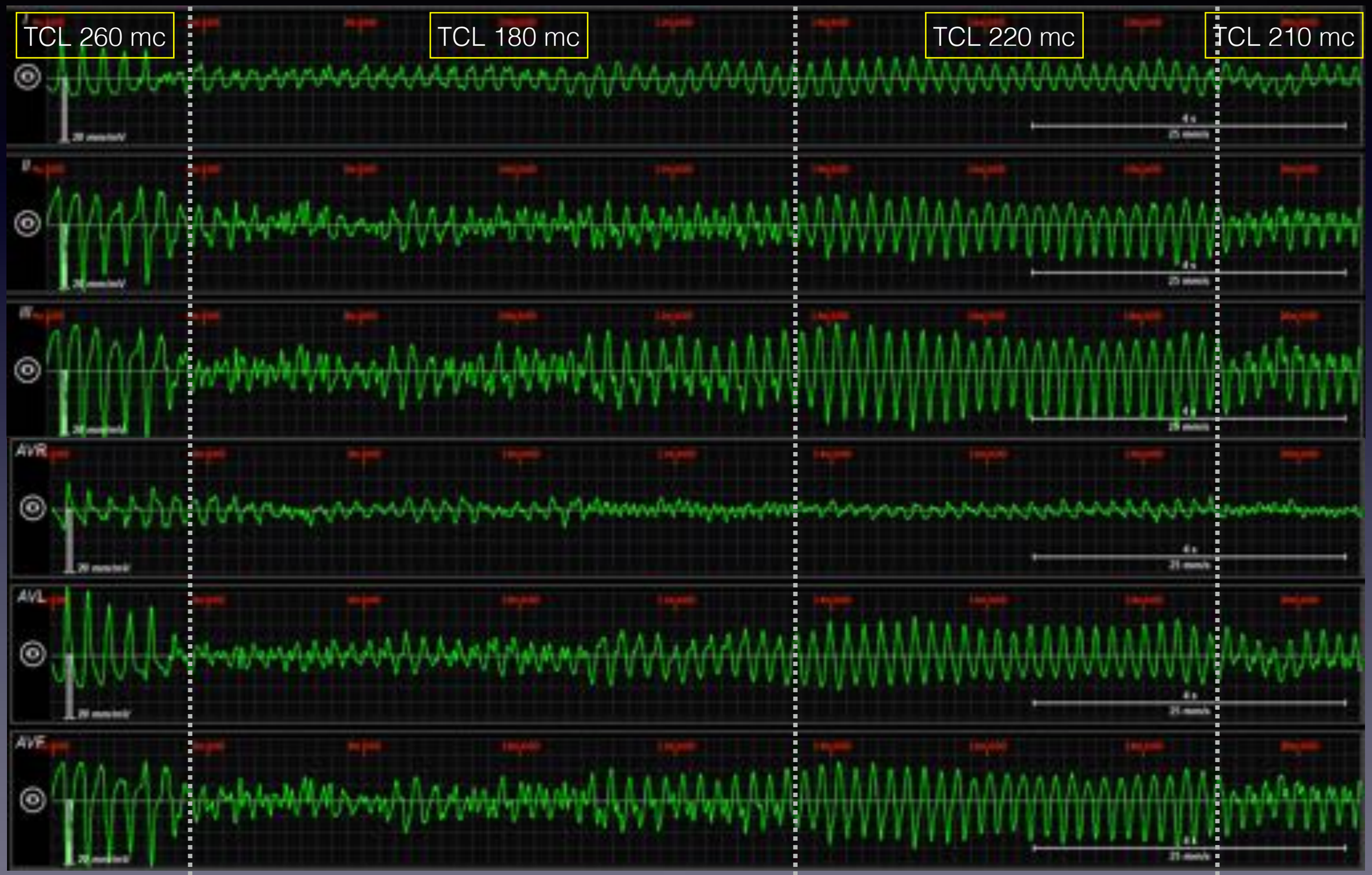

Periscar VT

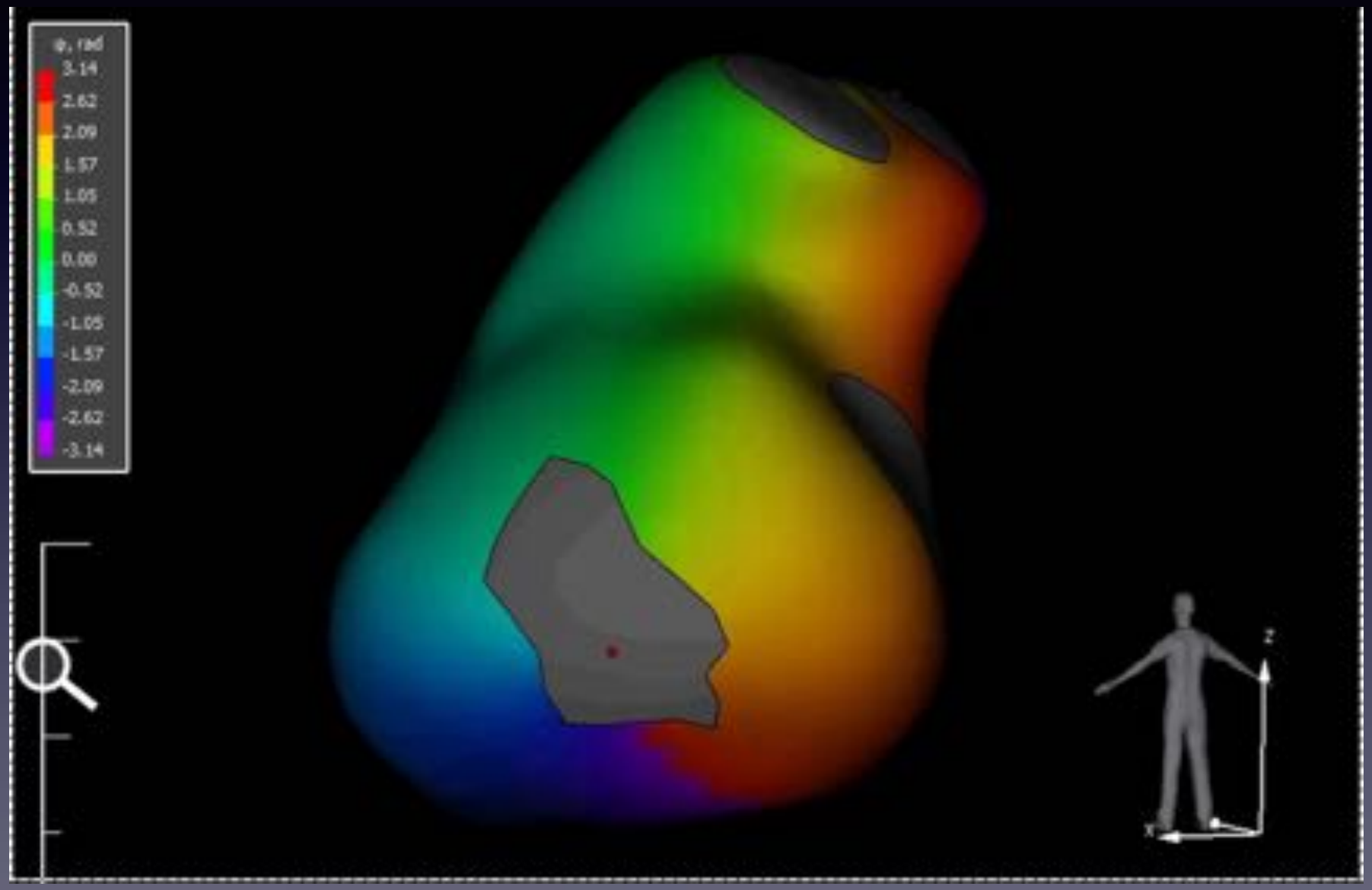

1st MMVT

CASE N 2 Perimitral VT

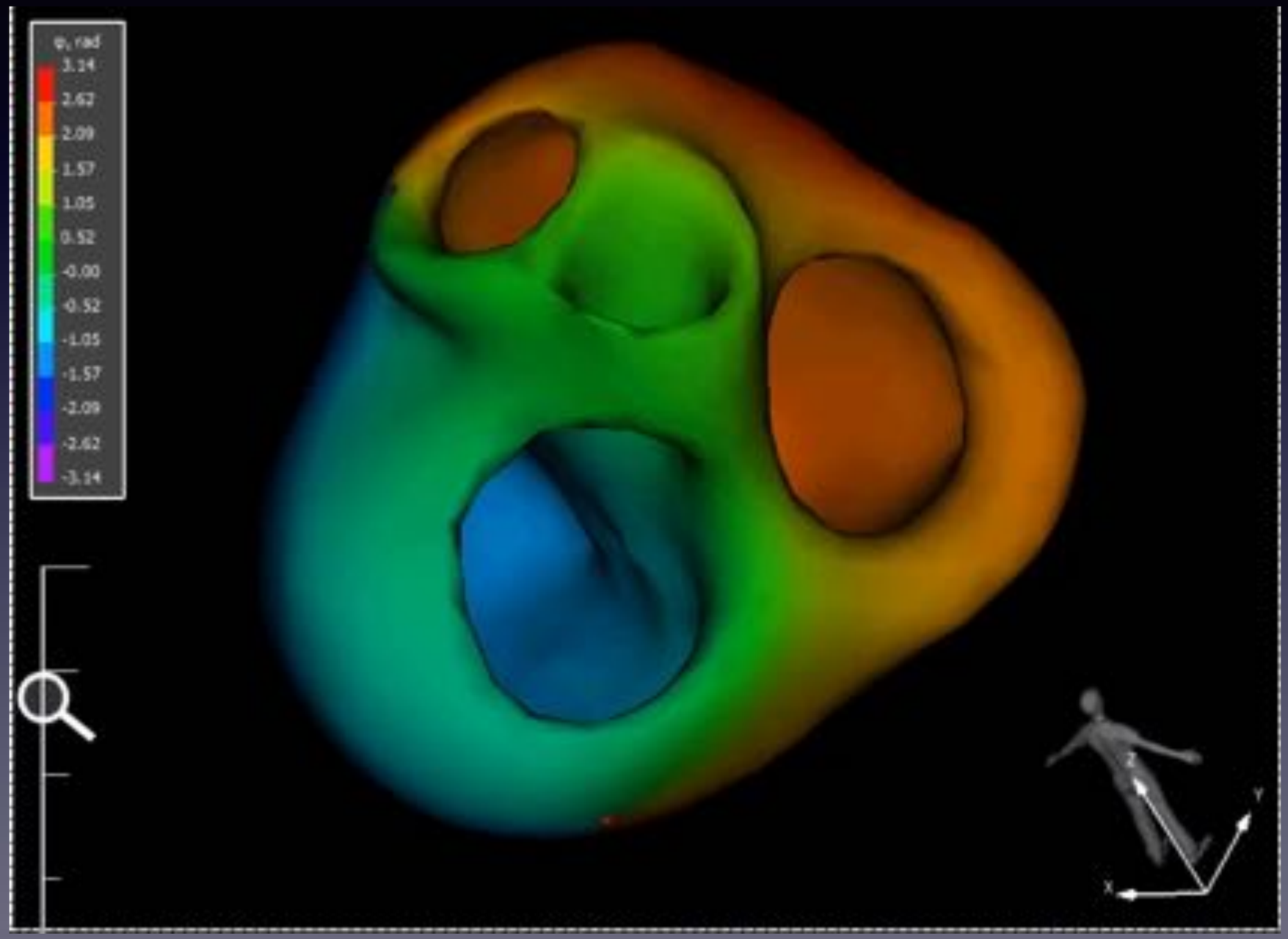

2nd MMVT

TCL 220 mc
6 s
ADM
FWD
PHASE
14s:020
5s:580
19s:600
20 mm/mV
2 s
50 mm/s

3rd MMVT

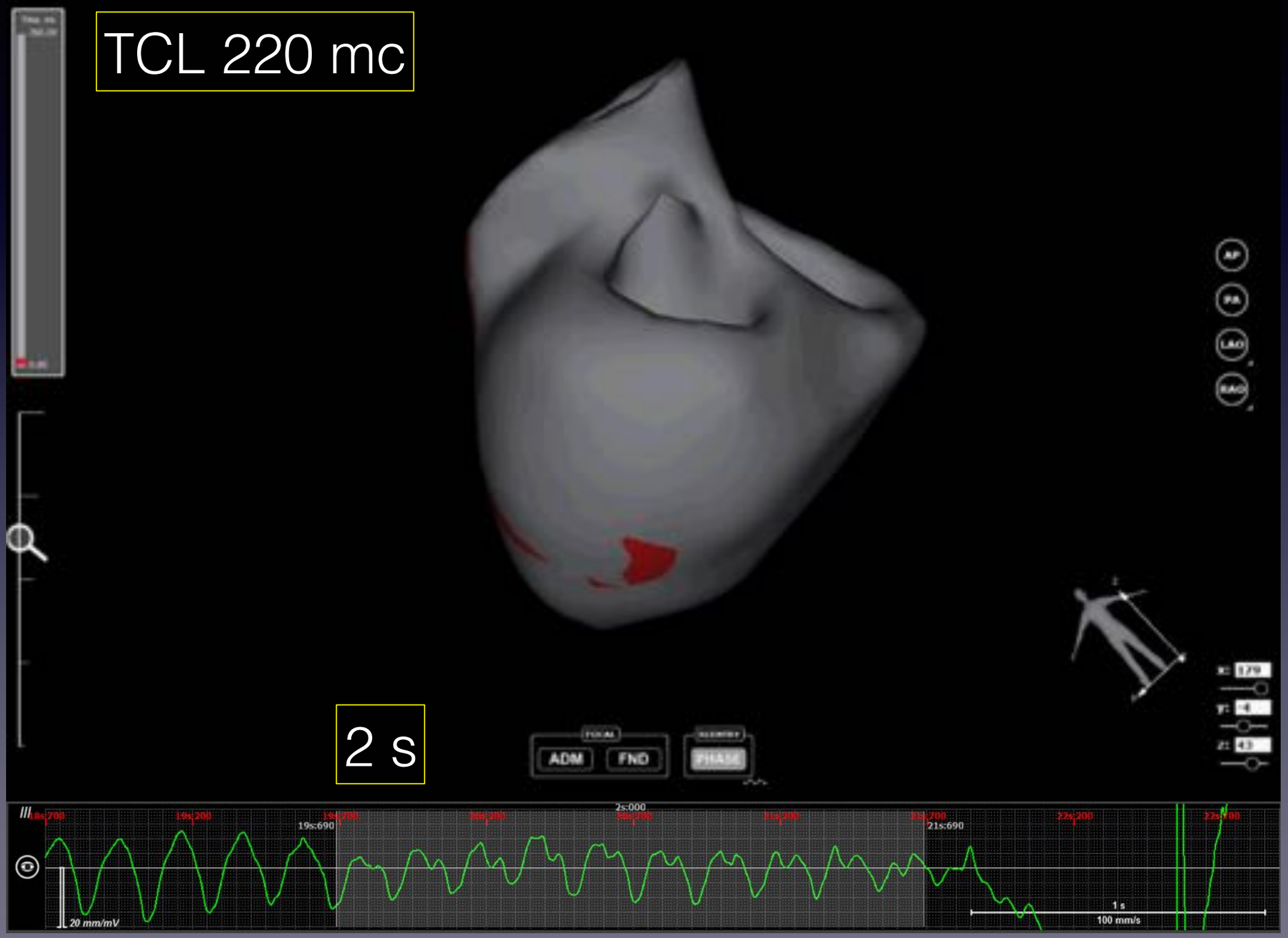
TCL 220 mc
2 s
ADM
FND
PHASE
19s:690
2s:000
21s:690
20 mm/mV
1 s
100 mm/s

CASE N 2 ECG

1st MMVT 2 s | PMVT 8 s | 2nd MMVT 6 s | 3rd MMVT 2 s

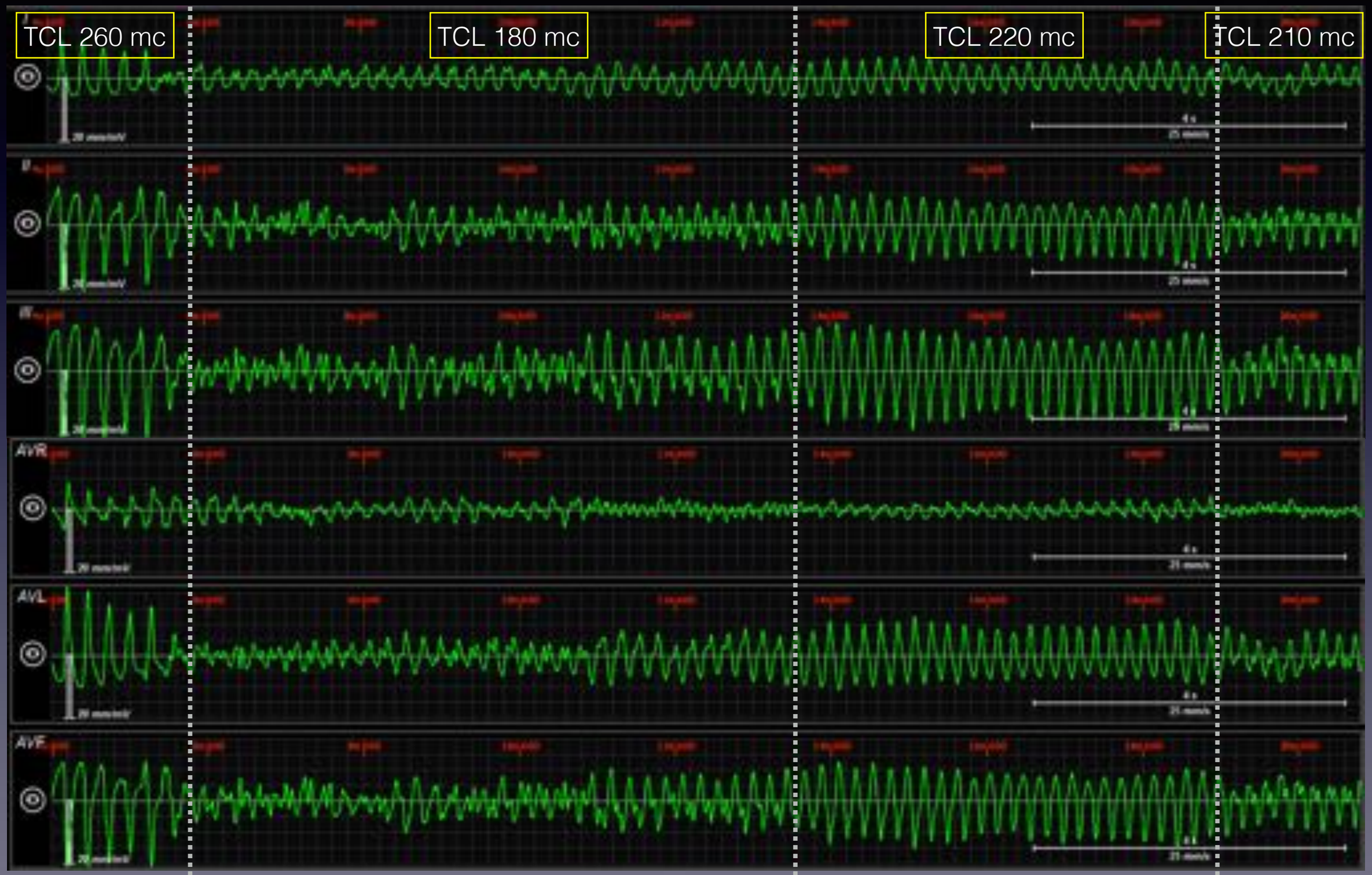

CASE N 3

38 y.o. female, Syncope, EF 60%
1233del in exon 10 of SCN5A, Positive Ajmaline test

CASE N 3

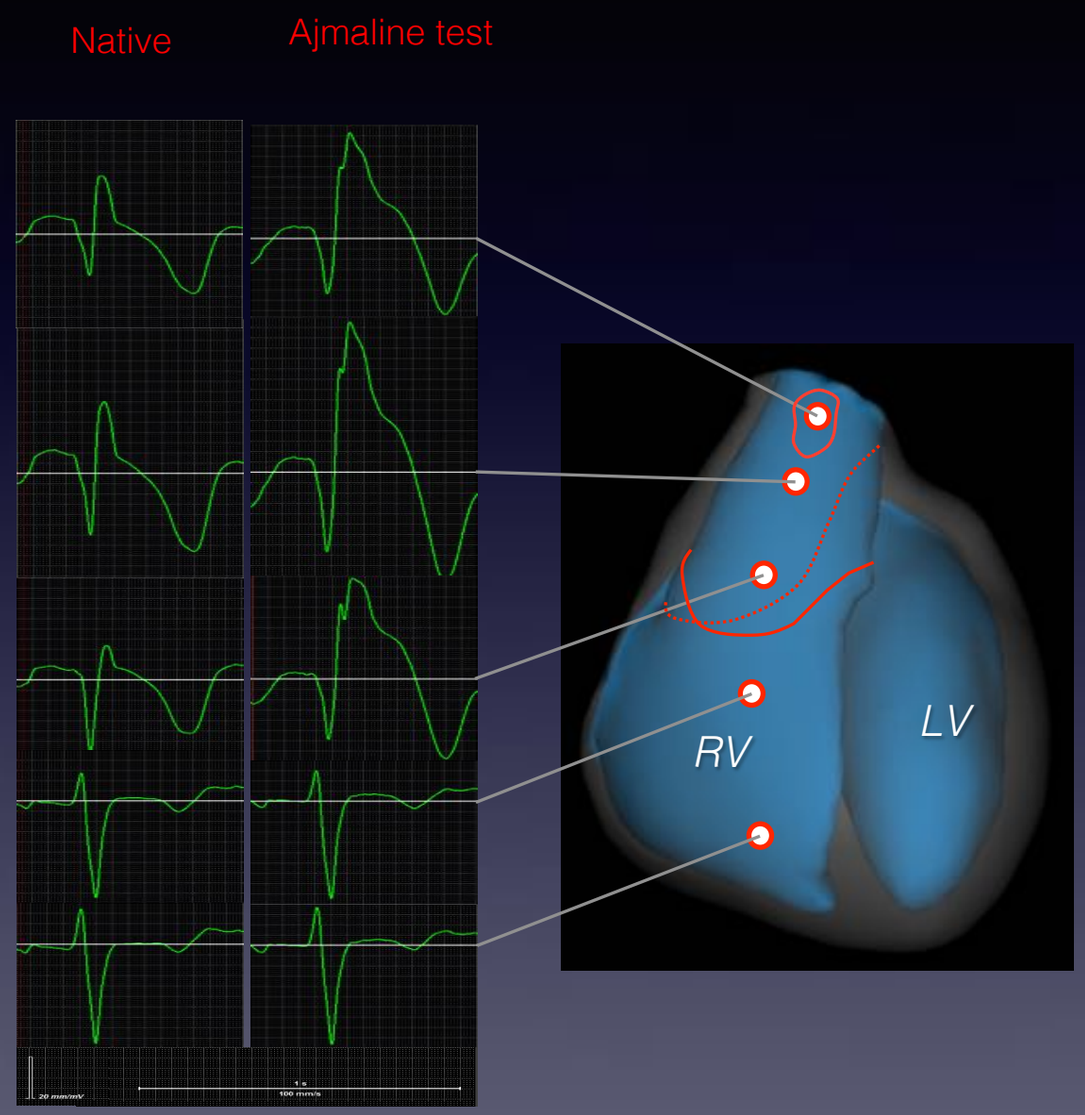
Native
Ajmaline test
RV
LV
20 mm/mV
1 s
100 mm/s

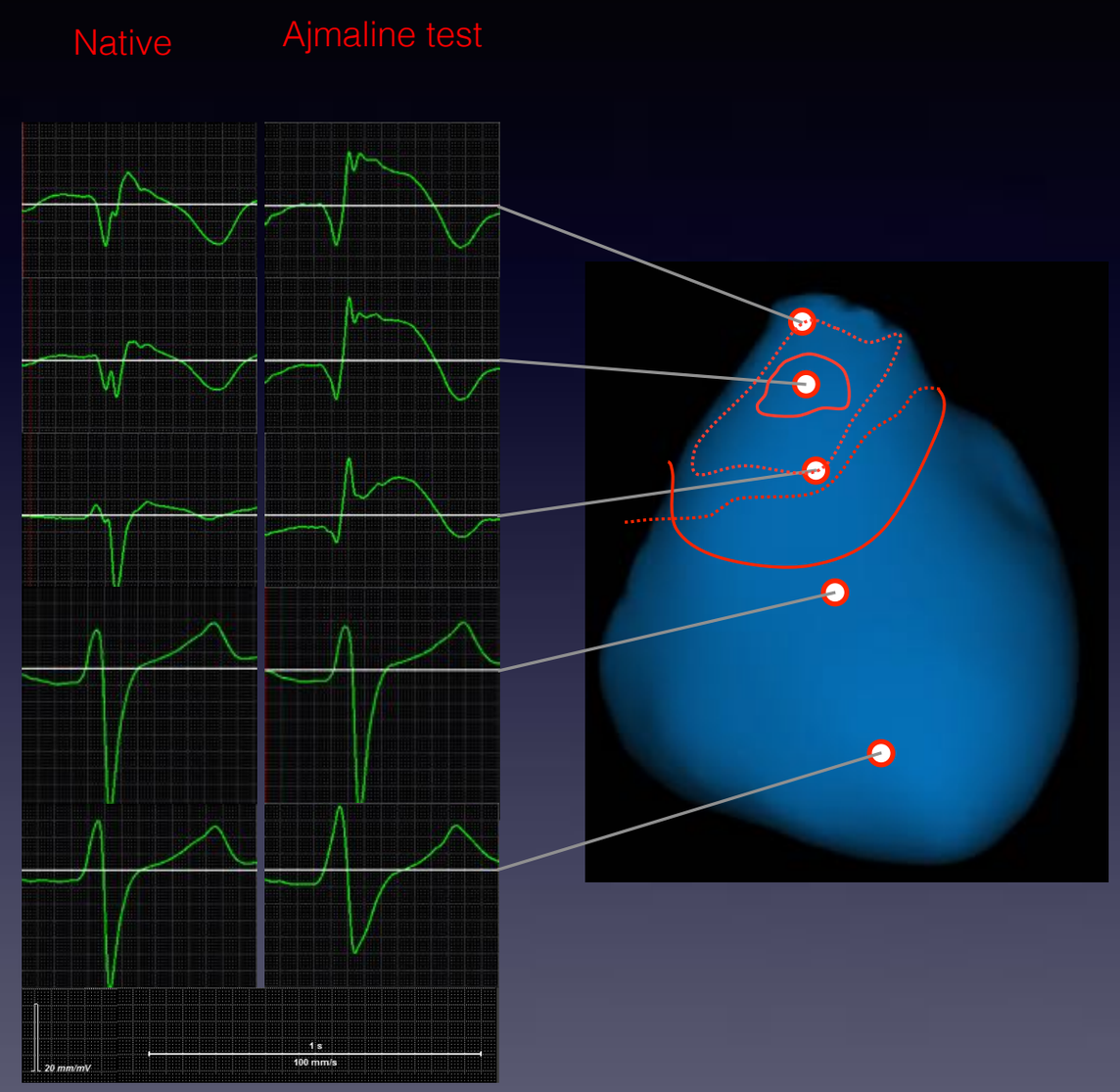
Native
Ajmaline test
20 mm/mV
1 s
100 mm/s

CASE N 3

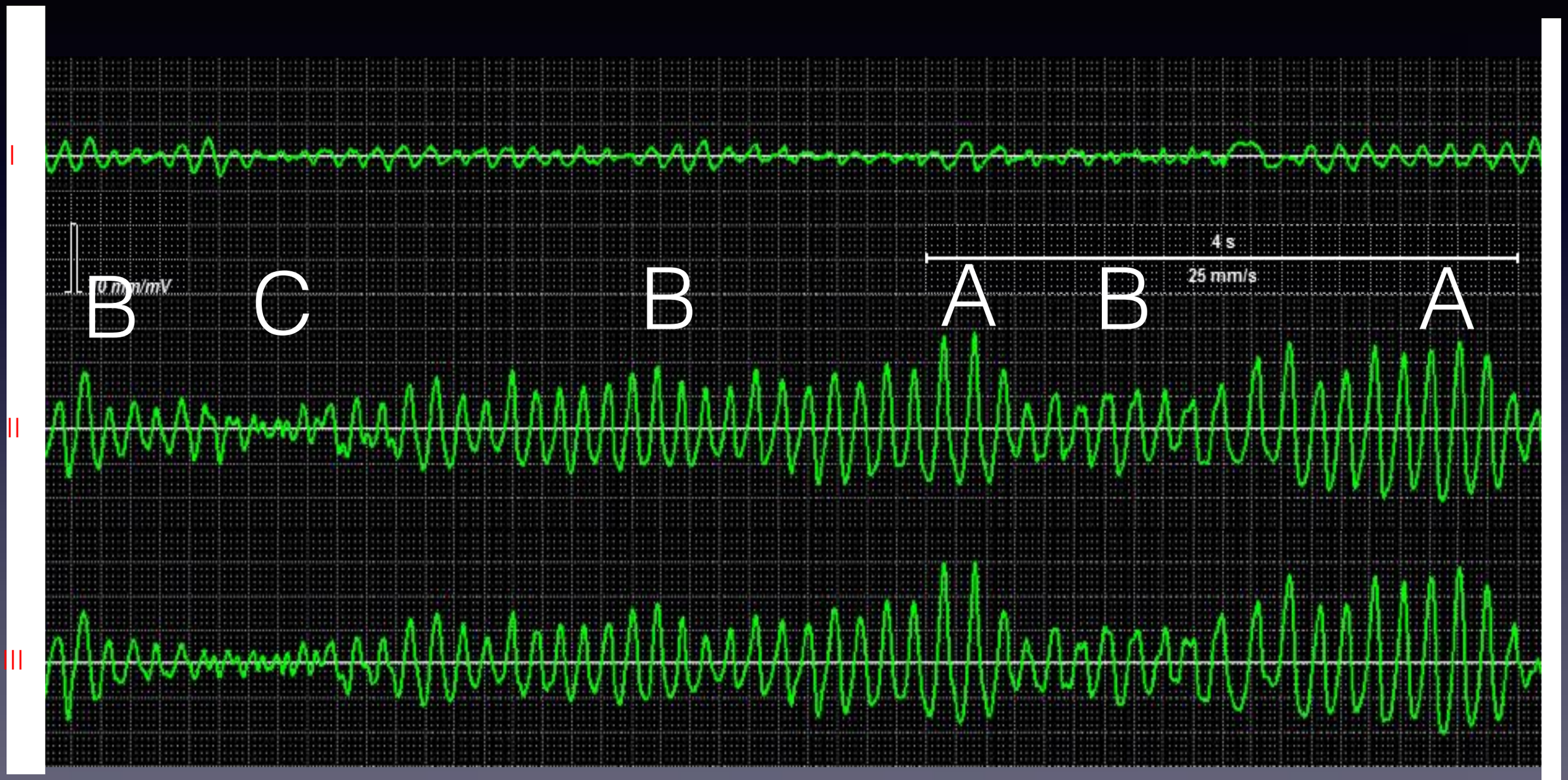

CASE N 3

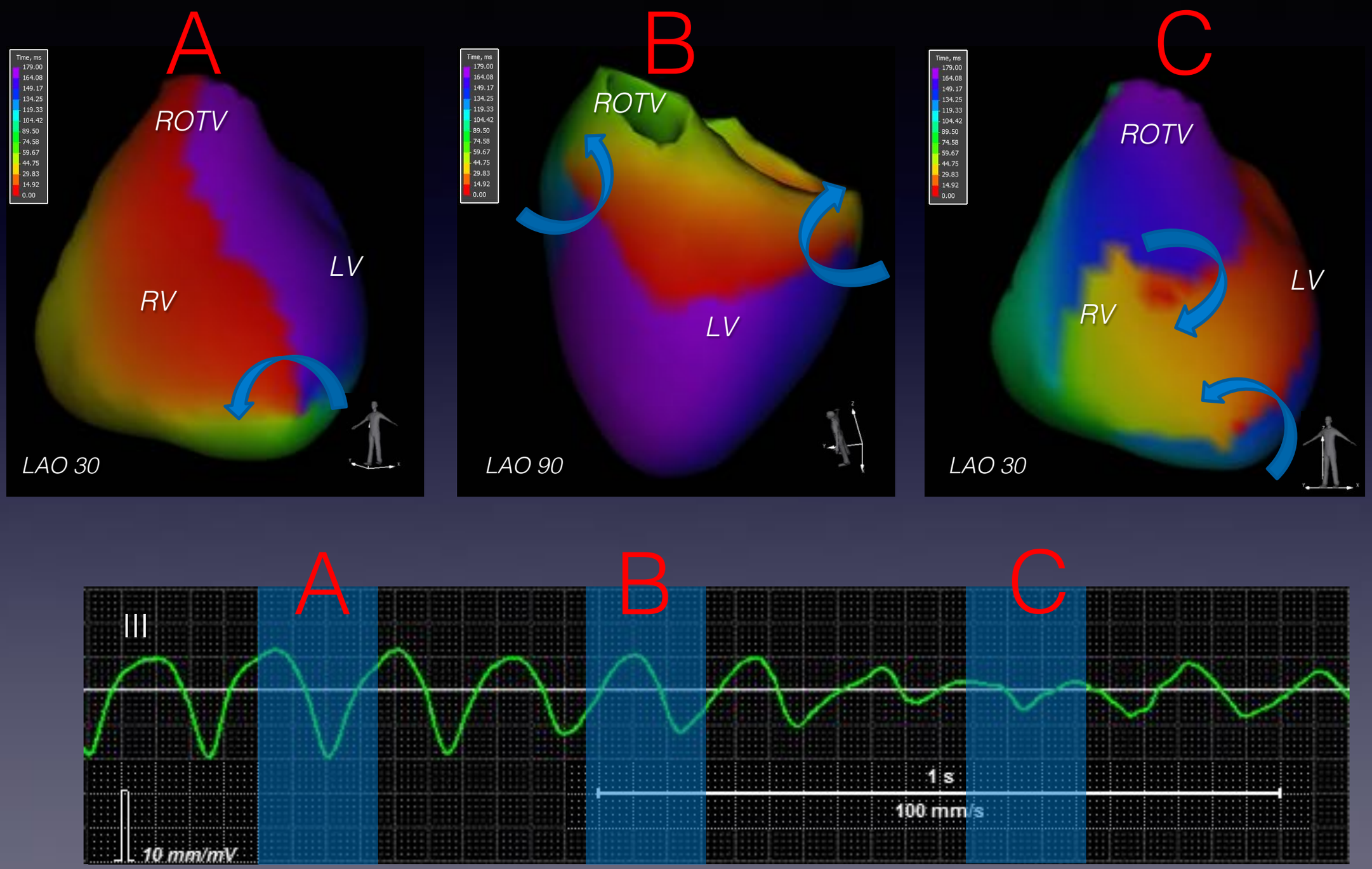
A
B
C
ROTV
LV
RV
LAO 30
LAO 90
Time, ms
179.00
164.08
149.17
134.25
119.33
104.42
89.50
74.58
59.67
44.75
29.83
14.92
0.00
III
1 s
100 mm/s
10 mm/mV

CASE N 3

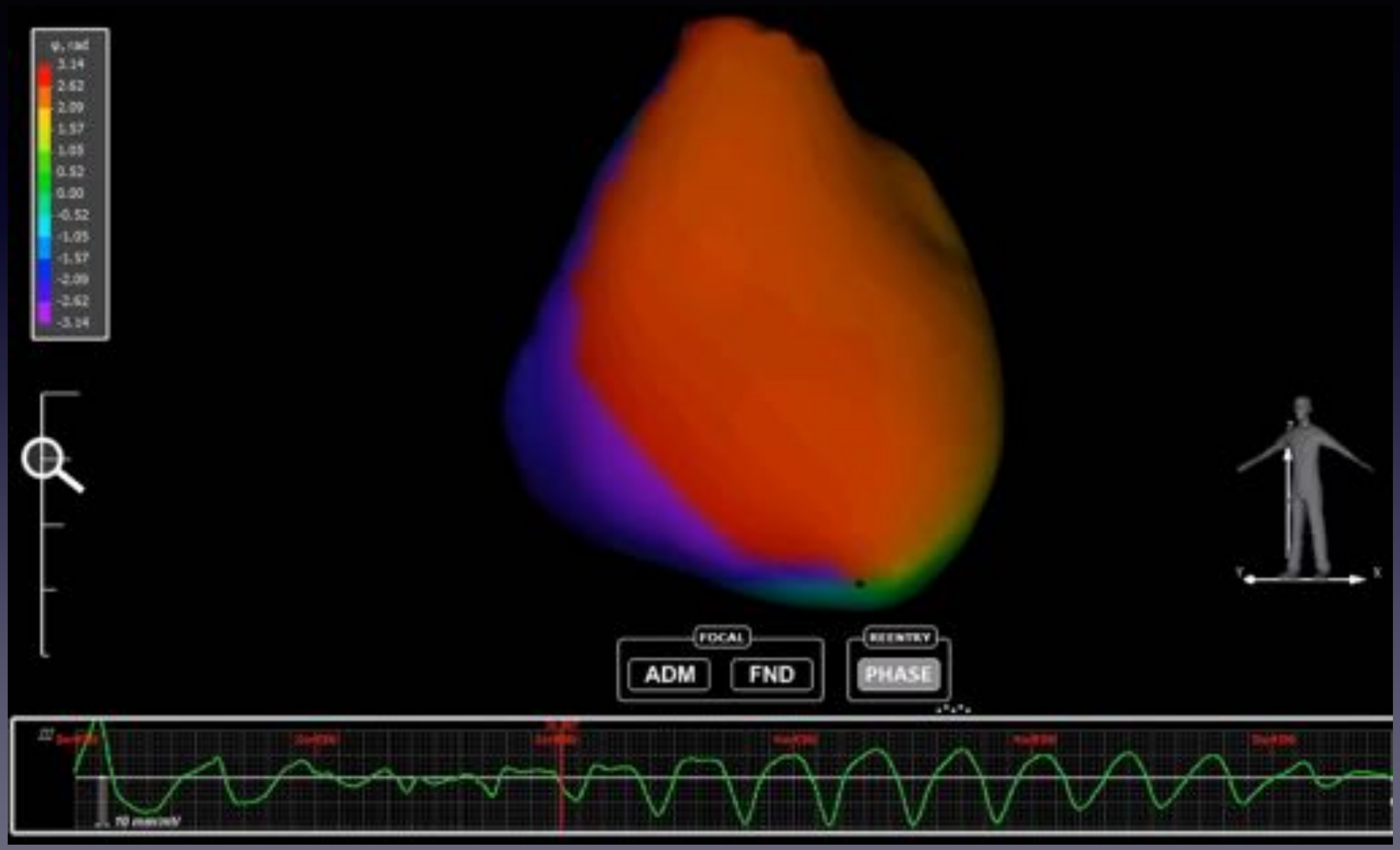
φ, rad
3.14
2.62
2.09
1.57
1.05
0.52
0.00
-0.52
-1.05
-1.57
-2.09
-2.62
-3.14
FOCAL
ADM
FND
REENTRY
PHASE

CASE N 3

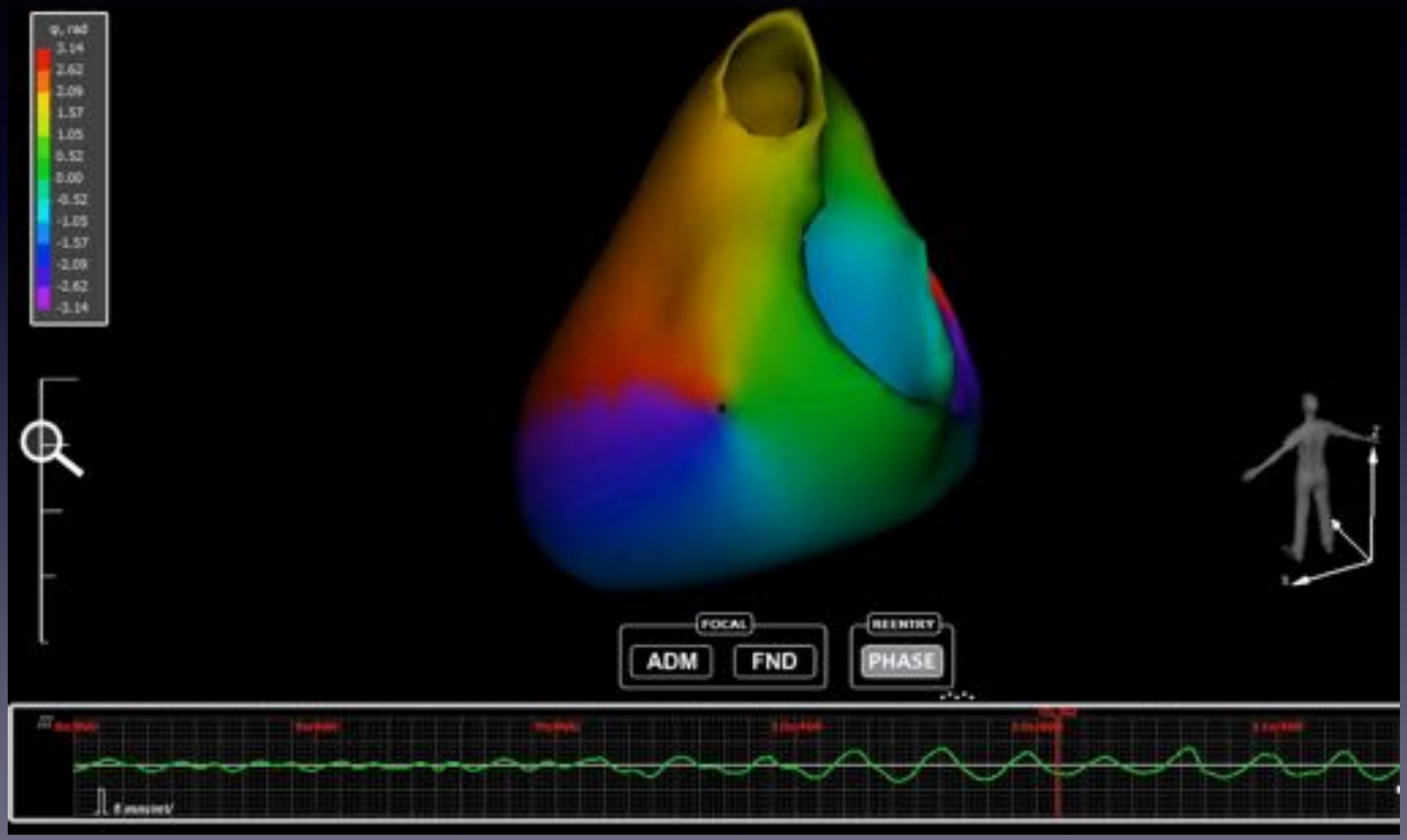
φ, rad
3.14
2.62
2.09
1.57
1.05
0.52
0.00
-0.52
-1.05
-1.57
-2.09
-2.62
-3.14
FOCAL
ADM
FND
REENTRY
PHASE

CASE N 3

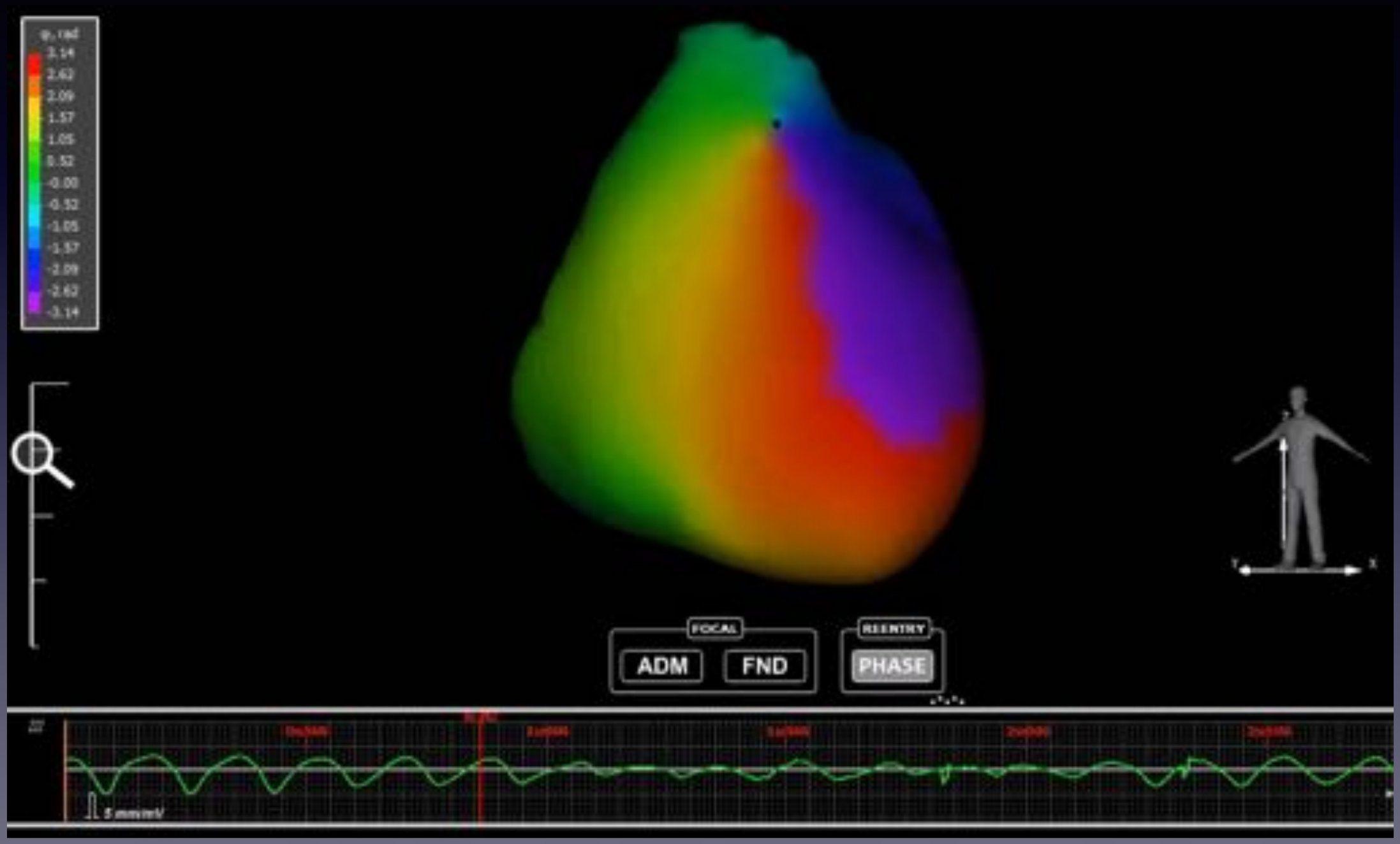
φ, rad
3.14
2.62
2.09
1.57
1.05
0.52
-0.00
-0.52
-1.05
-1.57
-2.09
-2.62
-3.14
FOCAL
ADM
FND
REENTRY
PHASE
5 mm/mV

Limitations

- Small group – no statistical data
- Unipolar electrogramms based phase mapping requited further validation

Conclusions

Noninvasive ECG imaging has demonstrated the ability to diagnose the mechanism (focal versus re-entrant) and accurately localize circuit of re-entrant ventricular arrhythmias

Noninvasive ECG imaging can detect local abnormal ventricular activities (late, fractionated or low voltage potentials) to provide for substrate mapping

Noninvasive ECG imaging contributes to overcome the difficulties of conventional mapping system in terms of polymorphic and/or non-tolerated ventricular tachycardia

Thank you very much for attention