Percutaneous Subxiphoid Epicardial Approach for Idiopathic Ventricular Arrhythmias.

Cristiano Pisani, Sissy Lara, Carina Hardy, Muhieddine Chokr, Hugo Bellotti, Franscisco Darrieux, Denise Hachul, Eduardo Sosa, Mauricio Scanavacca

Heart Institute - InCor – HC/FMUSP
São Paulo/SP

InCor HCFMUSP
Ciência e Humanismo

Venice, Italy October 16-18 2015 14th Edition
VENICE 2015 ARRHYTHMIAS

HC FMUSP

Percutaneous Subxiphoid Epicardial Approach for Idiopathic Ventricular Arrhythmias.

Cristiano Pisani

NO CONFLICT OF INTEREST TO DISCLOSE

Introduction

- One of the reasons for failure of failure of idiopathic ventricular arrhythmias ablation is the epicardial origin of the arrhythmia.
- They can be reached by the epicardial venous system, but sometimes the percutaneous subxyphoid mapping is necessary.

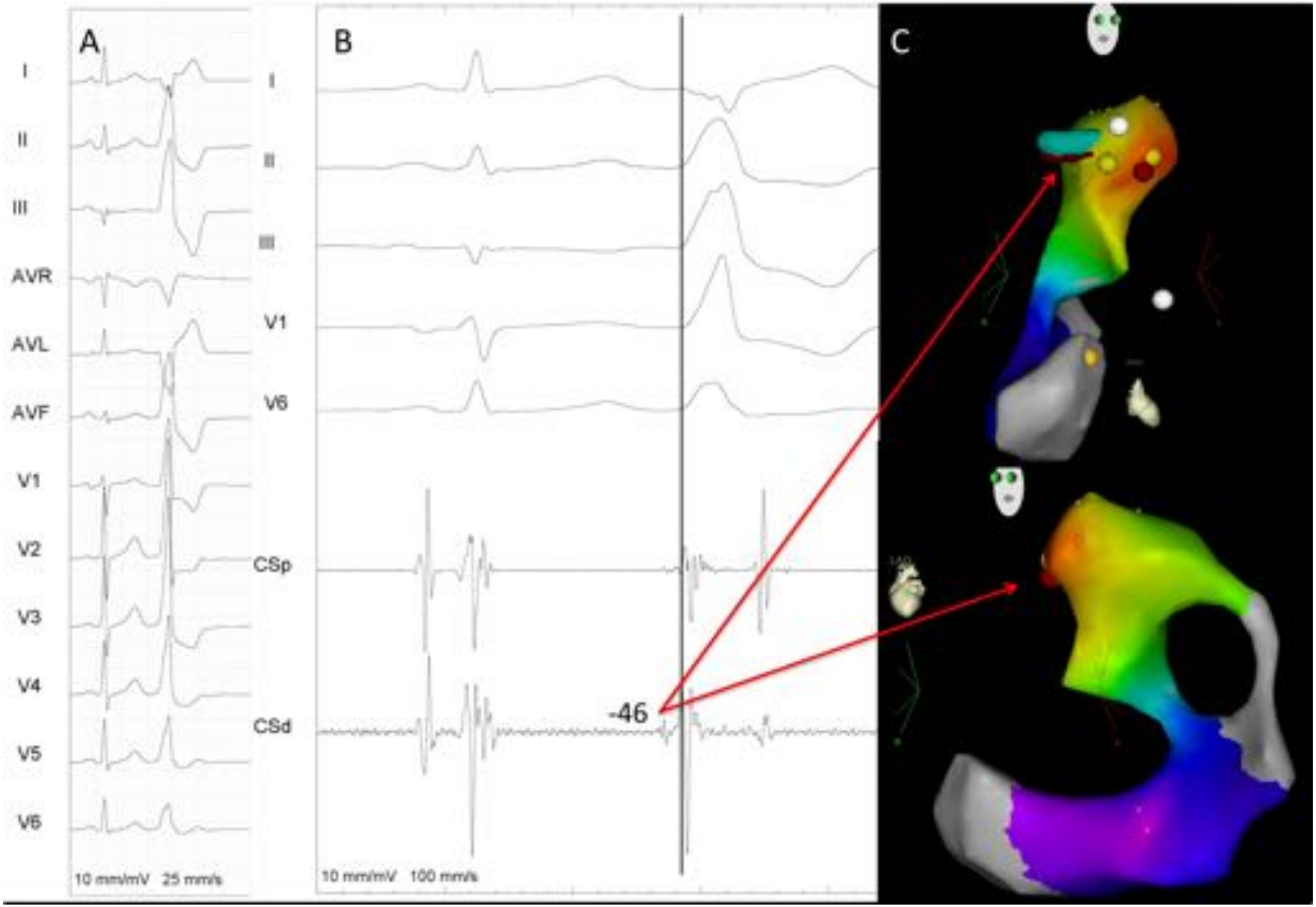
A
I
II
III
AVR
AVL
AVF
V1
V2
V3
V4
V5
V6
10 mm/mV 25 mm/s
B
I
II
III
V1
V6
CSp
CSd
-46
10 mm/mV 100 mm/s
C

Percutaneous Pericardial Instrumentation for Endo – Epicardial Mapping of Previously Failed Ablations

VT epicardial mapping in 20 patients with normal heart and unsuccessful endocardial ablation

Schweikert R et al. Circulation 2003.

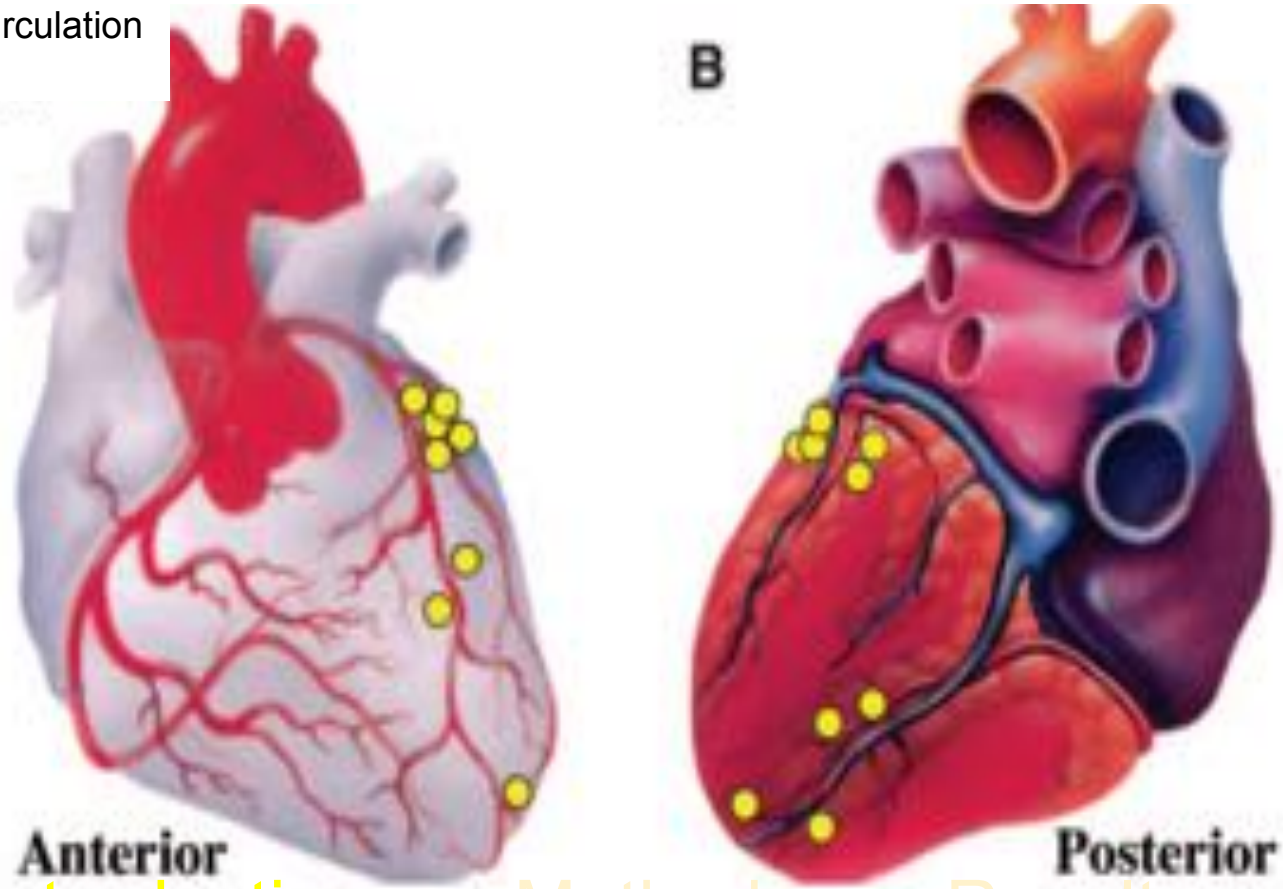

Objective:

- The object of this study is to evaluate epicardial mapping through subxiphoid puncture to ablate epicardial idiopathic ventricular arrhythmias

Methods:

- We evaluated all procedures performed in our institution between 2007 and 2015 and searched for patients that underwent subxiphoid puncture to map idiopathic ventricular arrhythmias.

Results:

- Nine Patients underwent subxiphoid puncture to epicardial mapping
  - Male Sex: 7 (77,8%)
  - Age: Median 32 (Q1: 25,5; Q3:38)
  - Previous Ablation Attempt: 1±0,9 (0-3)

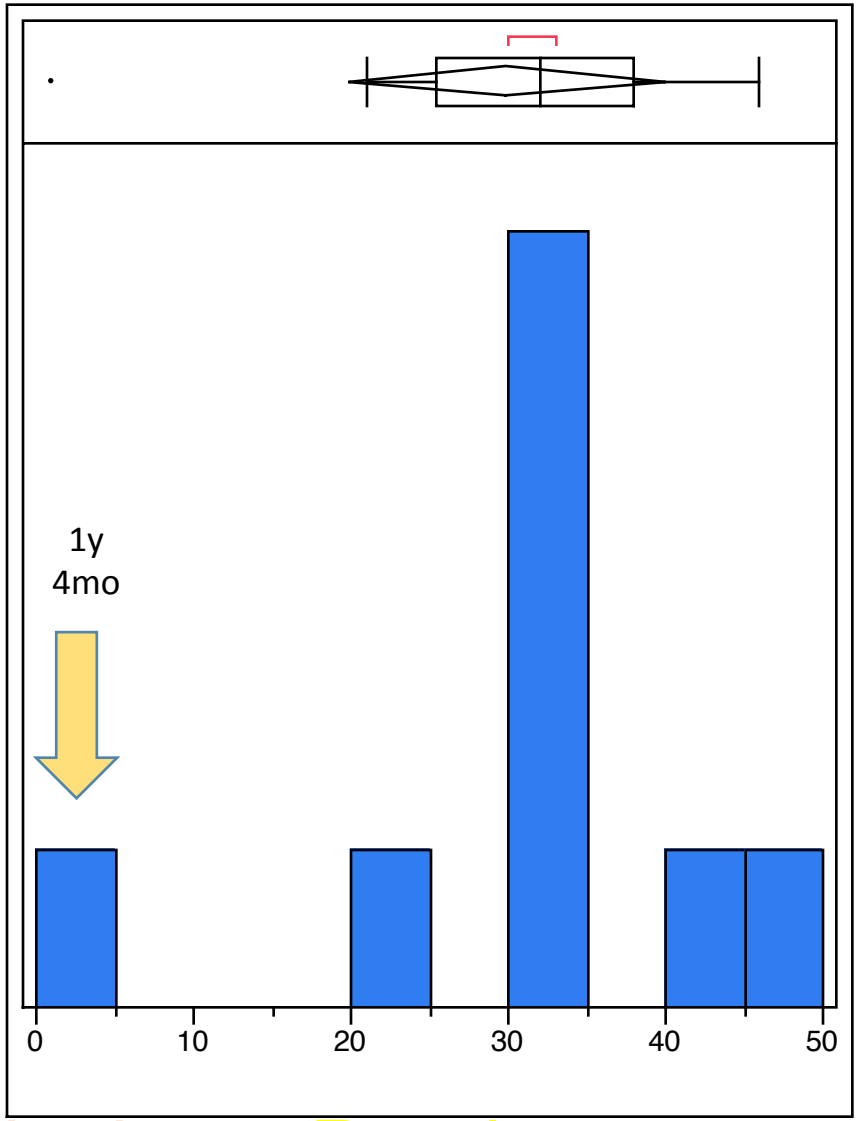

14733_15
I
II
III
AVR
AVL
AVF
V1
V2
V3
V4
V5
V6
10 mm/mV 25 mm/s

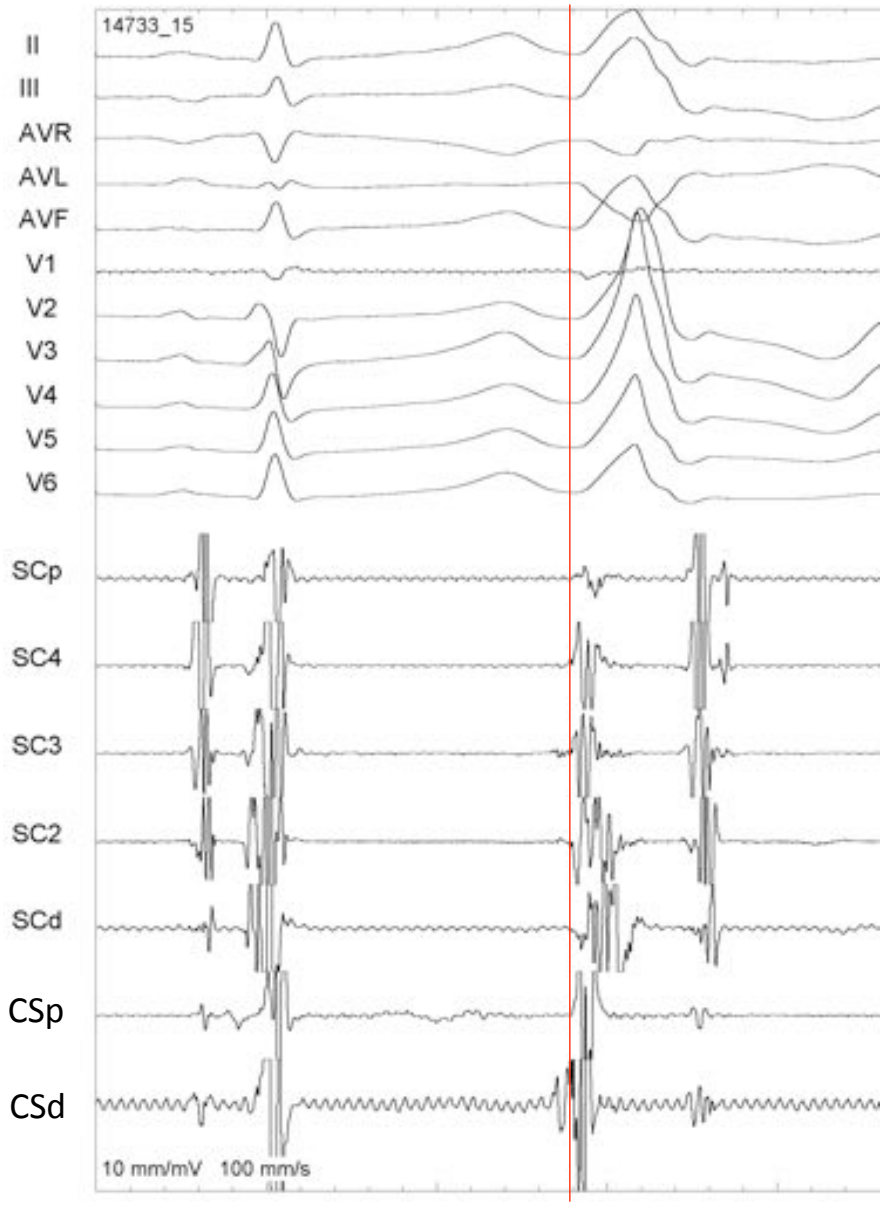
14733_15
II
III
AVR
AVL
AVF
V1
V2
V3
V4
V5
V6
SCp
SC4
SC3
SC2
SCd
CSp
CSd
10 mm/mV 100 mm/s

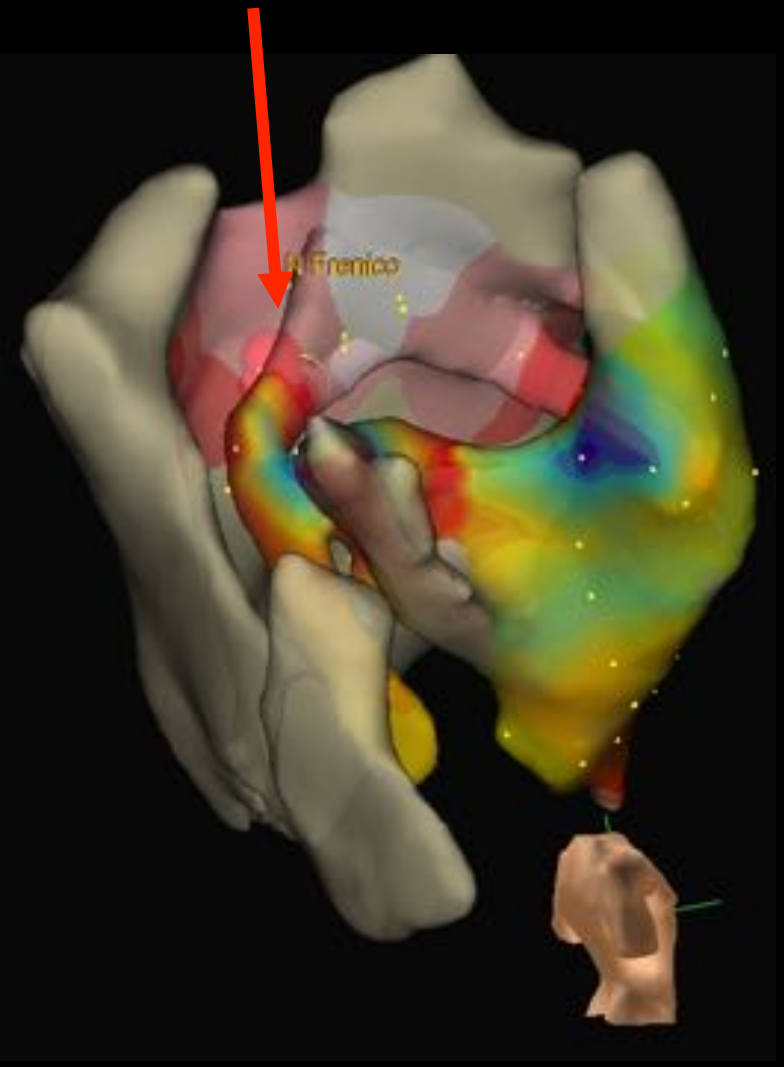
N Frenico

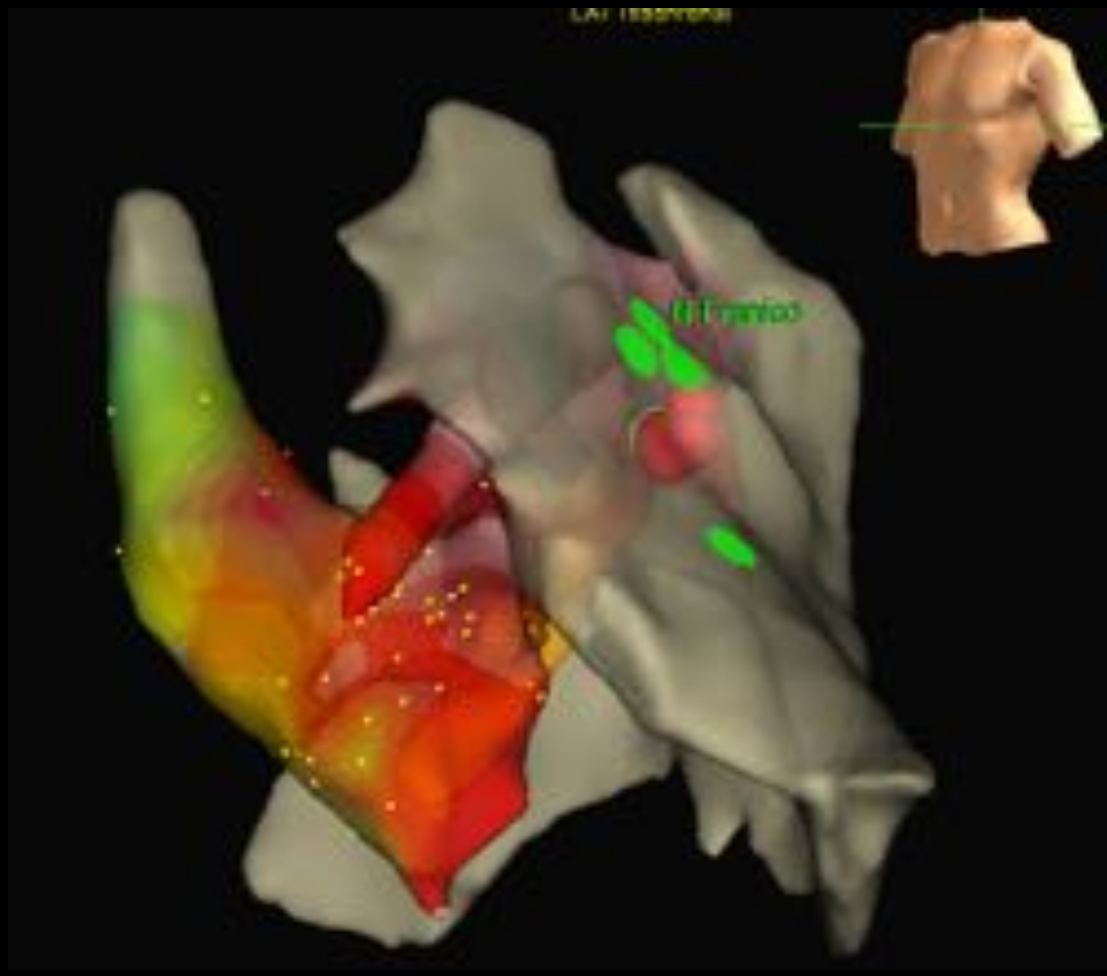
N Frenico

Pace Mapping Epi

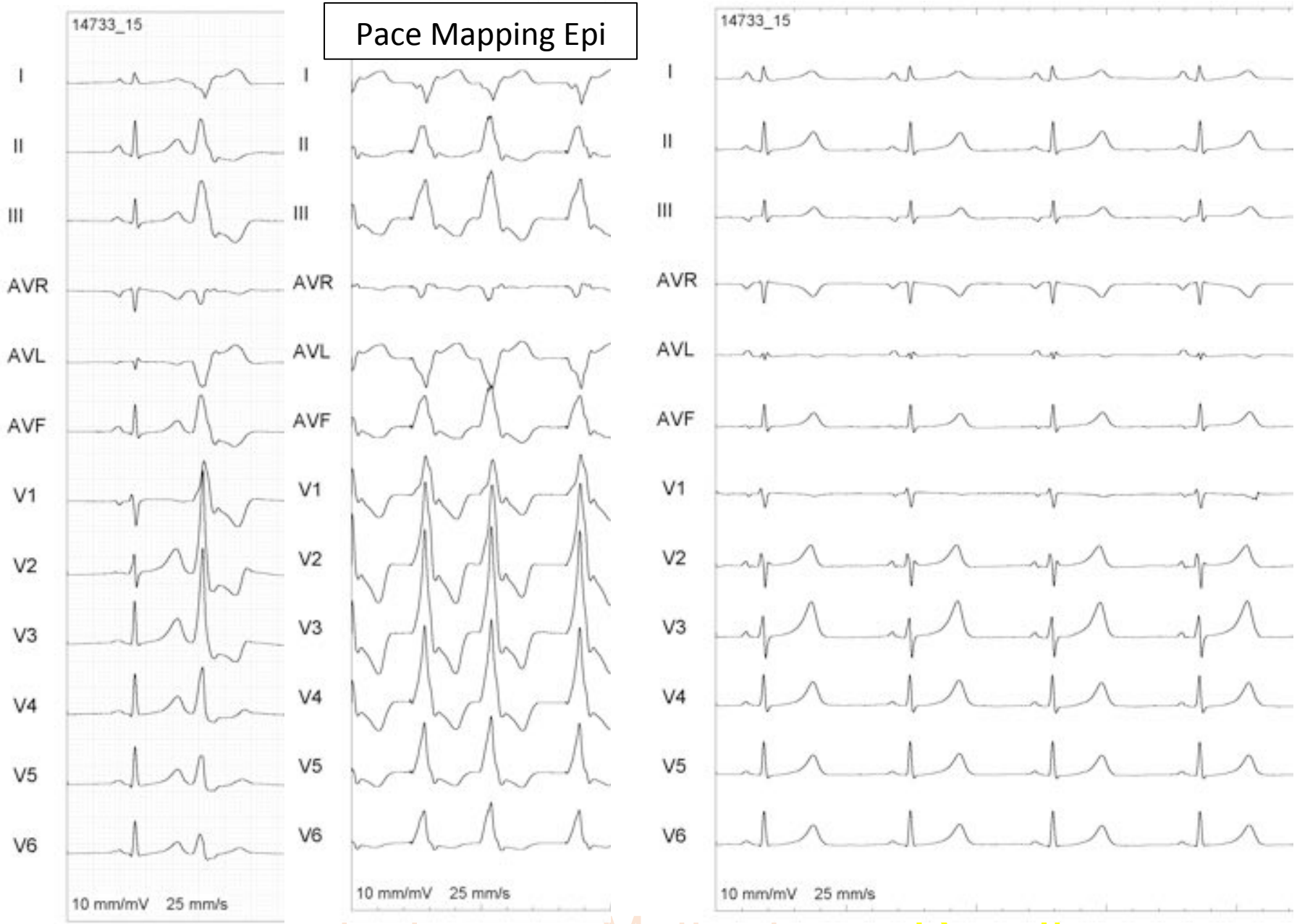

2 Months After Ablation

INCOR - INSTITUTO DO CORAÇÃO
Hospital das Clínicas da Faculdade de Medicina da USP
Rua Enéias de Carvalho Aguiar, 44
Fone: 2661 5533

Relatório de Holter

1 - Dados do Exame

Nº do Exame	Data do Exame: 18/03/2015 08:34	Código:
128	Protocolo: Holter de 3 canais	7BR-00923

2 - Dados do Paciente

Nome.
Sexo: F Altura: Peso: Idade: Fumante: Não

3 - Médico Solicitante

Nome: DR.CARLOS EDUARDO B. BRANCO Tel:
Clínica: INCOR Fax:

4 - Resumo Estatístico

Totais:

Duração (h):	23:59
Nº Total de QRS's:	119.980
Ectópicos Ventriculares:	1 (<1%)
Ectópicos Supraventriculares:	24 (<1%)
Artefatos (%):	<1

Freqüência Cardíaca:

Min: 52 bpm às 13:58:40
Média: 86 bpm
Máx: 146 bpm às 18:01:14

F.C >= 120 bpm durante 01:25:40 h
F.C. <= 50 bpm não evidenciada

Arritmias Ventriculares:

1 Isoladas, das quais
0 em 0 episódios de Bigeminismo
0 Episódios em Pares
0 Taquicardias

Arritmias Supraventriculares:

24 Isoladas
0 Pareadas
0 Taquicardias

Pausas

0 Pausas (>= 2,0 s.)

Depressão do ST

C1: 0 episódios
C2: 0 episódios
C3: 0 episódios

Elevação do ST

C1: 0 episódios
C2: 0 episódios
C3: 0 episódios

©2013 - Cardio Sistemas Comt. Indl. Ltda - www.cardios.com.br - Todos os direitos reservados - Versão 5.382.110.138.

INCOR - INSTITUTO DO CORAÇÃO
Hospital das Clínicas da Faculdade de Medicina da USP

Nº do Exame	Paciente:	Código:
128	Data do Exame: 18/03/2015 08:34:00	7BR-00923

©2013 - Cardio Sistemas Comt. Indl. Ltda - www.cardios.com.br - Todos os direitos reservados - Versão 5.382.110.138.

Pt	Gender	Age	Previous Ablation	Electroanatomic Mapping	Catheter	Ablation Site	Epi Success	Remapping Success	Complications	Close to coronary	Recurrence
#1	Male	33	1	No	4mm	RVOT Septal	No	Yes	No	No	No
#2	Male	21	3	Yes	8mm	Antero-septal Epi	Yes		1mm ST elevation in D1 and aVL	Yes	Yes
#3	Male	32	1	Yes	8mm	LV Infra Valvar	No	Yes	No	NR	No
#4	Male	30	1	No	8mm	LCC	No	Yes	No	No	No
#5	Male	1	0	No	4mm	Postero-basal	Yes		No	No	No
#6	Male	46	1	No	8mm	Antero-septal	No	No	No	Yes	Failure
#7	Male	43	1	No	8mm	NA	No	No	Hemopericardium with need of surgery	No	Failure
#8	Female	33	1	No	8mm	RCC	No	Yes	No	No	Late
#9	Female	30	0	Yes	8mm	LV Antero-lateral	Yes		No	No	No

Pt	Gender	Age	Previous Ablation	Electroanatomic Mapping	Catheter	Ablation Site	Epi Success	Remapping Success	Complications	Close to coronary	Recurrence
#1	Male	33	1	No	4mm	RVOT Septal	No	Yes	No	No	No
#2	Male	21	3	Yes	8mm	Antero-septal Epi	Yes		1mm ST elevation in D1 and aVL	Yes	Yes
#3	Male	32	1	Yes	8mm	LV Infra Valvar	No	Yes	No	NR	No
#4	Male	30	1	No	8mm	LCC	No	Yes	No	No	No
#5	Male	1	0	No	4mm	Postero-basal	Yes		No	No	No
#6	Male	46	1	No	8mm	Antero-septal	No	No	No	Yes	Failure
#7	Male	43	1	No	8mm	NA	No	No	Hemopericardium with need of surgery	No	Failure
#8	Female	33	1	No	8mm	RCC	No	Yes	No	No	Late
#9	Female	30	0	Yes	8mm	LV Antero-lateral	Yes		No	No	No

Pt	Gender	Age	Previous Ablation	Electroanatomic Mapping	Catheter	Ablation Site	Epi Success	Remapping Success	Complications	Close to coronary	Recurrence
#1	Male	33	1	No	4mm	RVOT Septal	No	Yes	No	No	No
#2	Male	21	3	Yes	8mm	Antero-septal Epi	Yes		1mm ST elevation in D1 and aVL	Yes	Yes
#3	Male	32	1	Yes	8mm	LV Infra Valvar	No	Yes	No	NR	No
#4	Male	30	1	No	8mm	LCC	No	Yes	No	No	No
#5	Male	1	0	No	4mm	Postero-basal	Yes		No	No	No
#6	Male	46	1	No	8mm	Antero-septal	No	No	No	Yes	Failure
#7	Male	43	1	No	8mm	NA	No	No	Hemopericardium with need of surgery	No	Failure
#8	Female	33	1	No	8mm	RCC	No	Yes	No	No	Late
#9	Female	30	0	Yes	8mm	LV Antero-lateral	Yes		No	No	No

Pt	Gender	Age	Previous Ablation	Electroanatomic Mapping	Catheter	Ablation Site	Epi Success	Remapping Success	Complications	Close to coronary	Recurrence
#1	Male	33	1	No	4mm	RVOT Septal	No	Yes	No	No	No
#2	Male	21	3	Yes	8mm	Antero-septal Epi	Yes		1mm ST elevation in D1 and aVL	Yes	Yes
#3	Male	32	1	Yes	8mm	LV Infra Valvar	No	Yes	No	NR	No
#4	Male	30	1	No	8mm	LCC	No	Yes	No	No	No
#5	Male	1	0	No	4mm	Postero-basal	Yes		No	No	No
#6	Male	46	1	No	8mm	Antero-septal	No	No	No	Yes	Failure
#7	Male	43	1	No	8mm	NA	No	No	Hemopericardium with need of surgery	No	Failure
#8	Female	33	1	No	8mm	RCC	No	Yes	No	No	Late
#9	Female	30	0	Yes	8mm	LV Antero-lateral	Yes		No	No	No

Conclusions:

- Epicardial approach to ablate epicardial outflow tract ventricular arrhytmias is an alternative to eliminate the arrhythmia when previous endocardial ablation failed.