

# *Syncope 2015 Update*

## **Case Study #3**

Brian Olshansky MD  
Professor Emeritus, University of Iowa  
Electrophysiologist, Mason City, Iowa USA

## **MY CONFLICTS OF INTEREST ARE**

**Medtronic – consultant**

**Boston Scientific – DSMB, consultant, research**

**Amarin – DSMB, consultant**

**Biocontrol – consultant, research**

**Sanofi-Aventis - DSMB**

**Boehringer Ingelheim – consultant, research**

**On-X - consultant**

**Biotronik - consultant**

**Lundbeck – consultant**

**Daiichi Sankyo – consultant, speaker**



# Collapse in Front of TV

- 68 yo male found by wife to be unresponsive in a chair while watching soccer
- When aroused, he thought he might have fallen asleep
- When paramedics arrived, he was awake and alert. BP = 160/90 and a regular pulse of 75
- He was transported to the ED

# 68 yo Male - Collapse

## *Additional History*

- He ate breakfast that AM
- He had a beer while watching TV
- Prior anterior wall infarction, LAD occlusion, LVEF - 45%, LV clot
- NYHA FC II CHF, HTN, diabetes, arthritis
- Meds: metoprolol 50 BID, lisinopril 10 BID, furosemide 40 QD, amlodipine 5 BID, aspirin 81 QD, insulin, warfarin

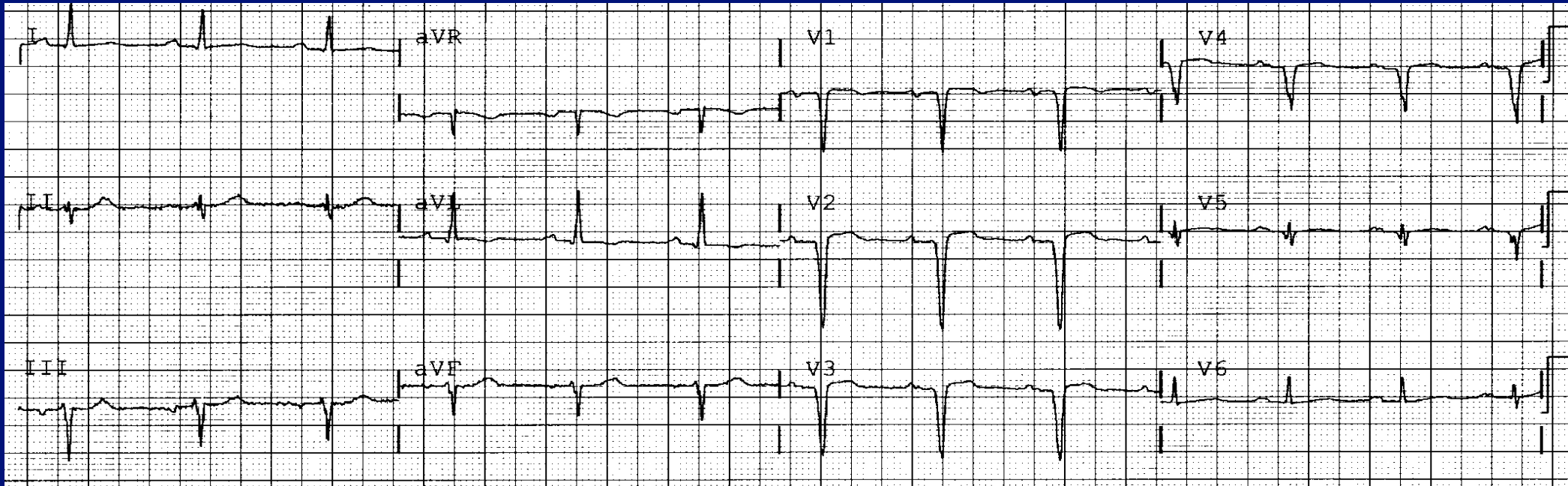
# 68 yo Male - Collapse

## *Physical in the ED*

- BP supine = 160/95, HR=70
- BP standing = 120/80, HR 75 @ 2 minutes
- Exam unremarkable except an S4 gallop, a II/VI systolic murmur and bibasilar rales

# 68 yo Male - Collapse

## *Electrocardiogram*



# Next Steps?

- Labs? Which? Why? BNP? Troponin?
- Stool Guaiac?
- Echocardiogram?
- CT Scan?
- Admit? Why?

# 68 yo Male – Admitted

- Tilt table test was performed -> considered “positive”
- He was sent home with an event monitor

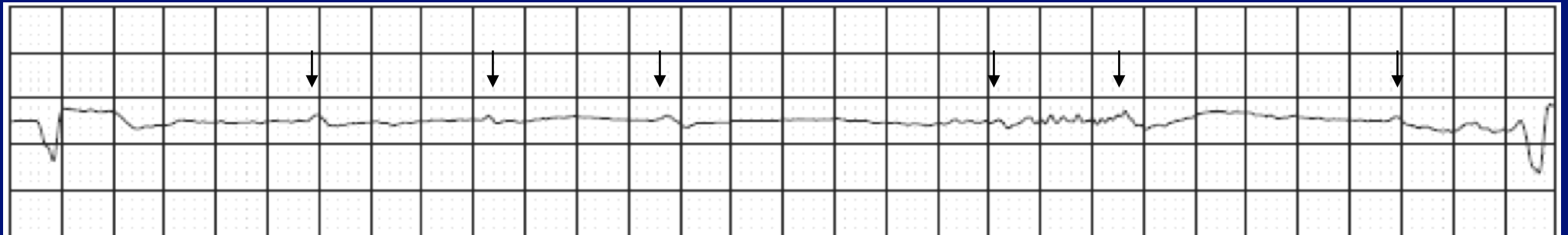
**Is this reasonable?**

**Any medications need adjustment?**



# 68 yo Male – Collapse

## *Event Monitor Recording*



**This was not associated with syncope**

# Next Steps?

- Pacemaker?
- Other testing? What?

S1S1: 390

500 ms

I

aVF

V1

V5

HISp

HISd

RV

Stim

A

A

A

H

H

H

500 ms

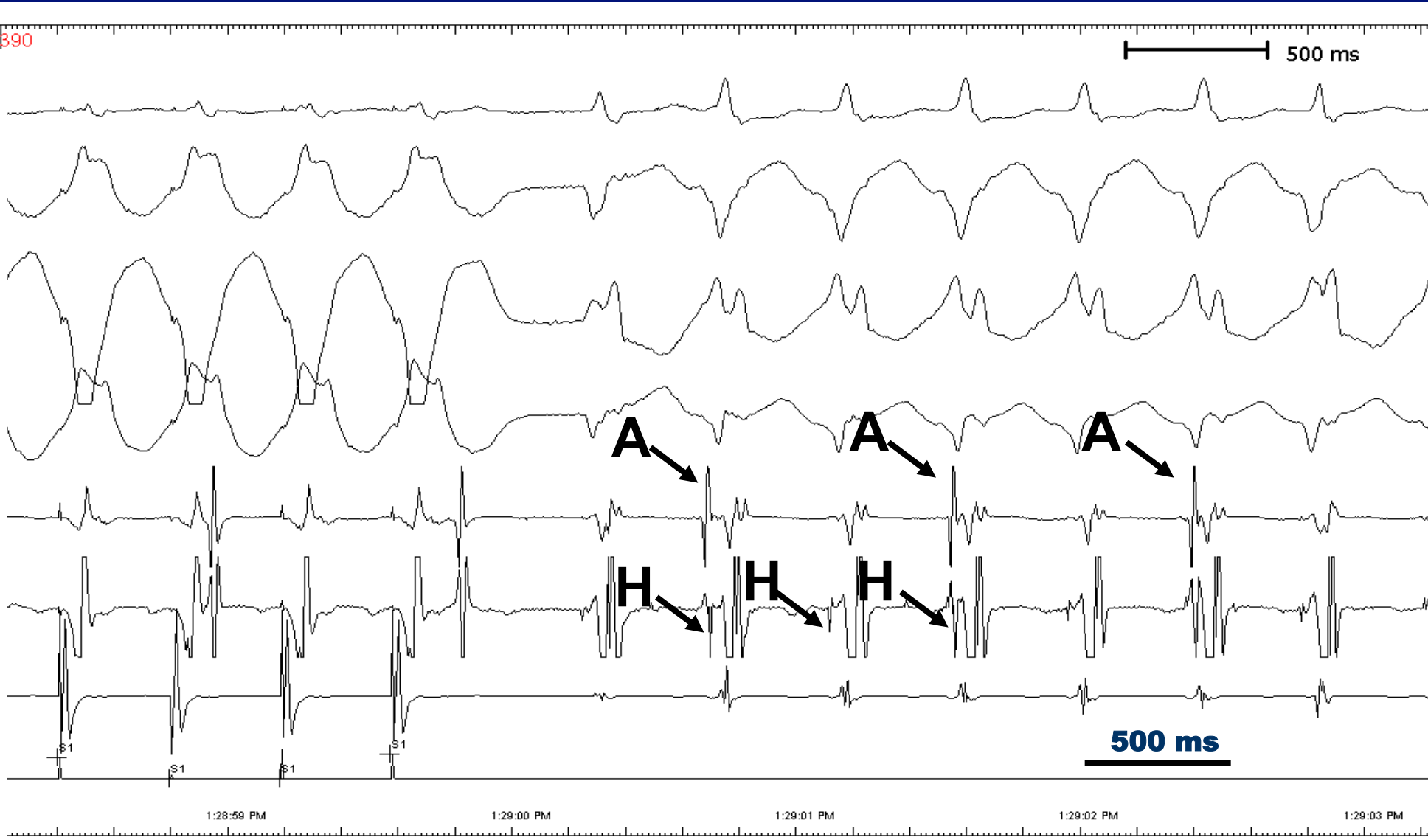
1:28:59 PM

1:29:00 PM

1:29:01 PM

1:29:02 PM

1:29:03 PM



**What is the best therapeutic approach?**

# Summary

- “Collapse” in a 68 yo male with heart failure and prior myocardial infarction
- Orthostatic hypotension
- Heart block – paroxysmal
- Ventricular tachycardia - induced