Indications for temporary and permanent pacing in ACS

Basri Amasyalı, MD
TOBB Etu Hospital
Ankara/Turkey

Disclosures

- No conflict of interest to declare

- Bradyarrhythmias and conduction defects are relatively common after ACS
- They are the result of both
  - autonomic stimulation
  - ischemia or necrosis of the conduction system.

The need for cardiac pacing ?

- Two major factors determine the need for cardiac pacing:

  (1) symptoms associated with bradyarrhythmia

  (2) the site of conduction abnormality

In the setting of an ACS;

- Different types of conduction disturbances may become manifest:
  - abnormalities of sinus impulse formation or conduction,
  - disorders of AV conduction,
  - disorders of intraventricular conduction

- In general, any patient with bradyarrhythmias that are associated with symptoms or cause hemodynamic compromise must be treated.

Sinus node abnormalities

- Sinus bradycardia, sinus arrest, sinoatrial exit block
- Incidence: 5% - 30%
- Abnormalities of sinus rhythm are more common, with inferoposterior infarction:
  - Same arteries supply the sinus node.
  - Chemically mediated activation of vagal receptors
- Treatment is not necessary, unless symptoms are present
- Atropine may be useful
- If bradycardia is prolonged and severe, or is not responsive to atropine, temporary cardiac pacing is indicated.

Disorders of AV conduction

- AV block occurs in 12–25% of patients with acute ACS.
  - First-degree AV block 2–12%
  - Second-degree AV block in 3–10%
  - Third-degree AV block in 3–7% of patients.

- The majority of patients have evidence of an inferoposterior infarction (approximately 70%).
  - Same arteries supply the AV node.
  - Activation of cardiac reflexes with augmentation of parasympathetic tone
  - Releasing of adenosine caused by inferior ischemia or infarction.

Harpaz D, et al. J Am Coll Cardiol 1999; 34:1721–8.

1° ← AV block → 3°

- The risk of progression;
  - from first-degree AV block to high-grade AV block (during inferior infarction) varies 10%-30%
  - from second-degree AV block to complete heart block is approximately 35%.
- The development of high-grade AV block in the setting of acute inferoposterior infarction is usually associated with narrow QRS complex escape rhythms
- The junctional escape rhythm usually remains stable at 50–60 bpm and can be increased by intravenous atropine,
- Even complete AV block may not require temporary pacing in this situation

Petrina M, et al. Am Heart J. 2006;152:11– 8.


V1
II
V5

Therapy in AV block$_1$

- Type I second-degree AV block with a narrow QRS
  - almost always represents a conduction block in the AV node, and temporary cardiac pacing is rarely required unless the patient is symptomatic.
- Type I second degree AV block with a wide QRS complex
  - may represent a conduction block in the AV node or His bundle
  - especially in the setting of anterior MI, temporary prophylactic pacing must be considered.
- In patients with type II second-degree AV block and
  - a wide QRS complex in the setting of inferior infarction, or
  - during an anterior MI (QRS width not important), a temporary pacemaker should be inserted.
- Type II second-degree AV block with a narrow QRS complex in the setting of inferior infarction
  - rarely progress to complete heart block

High grade AV block and anterior MI

Therapy in AV block$_2$

- High-grade AV block complicating an anterior wall infarction is usually located within the His–Purkinje system.
- In general, an interruption of the blood supply to the anterior wall and the interventricular septum severe enough to cause AV block usually causes severe LV dysfunction.
- Emergency temporary pacing is indicated in these patients subgroup.

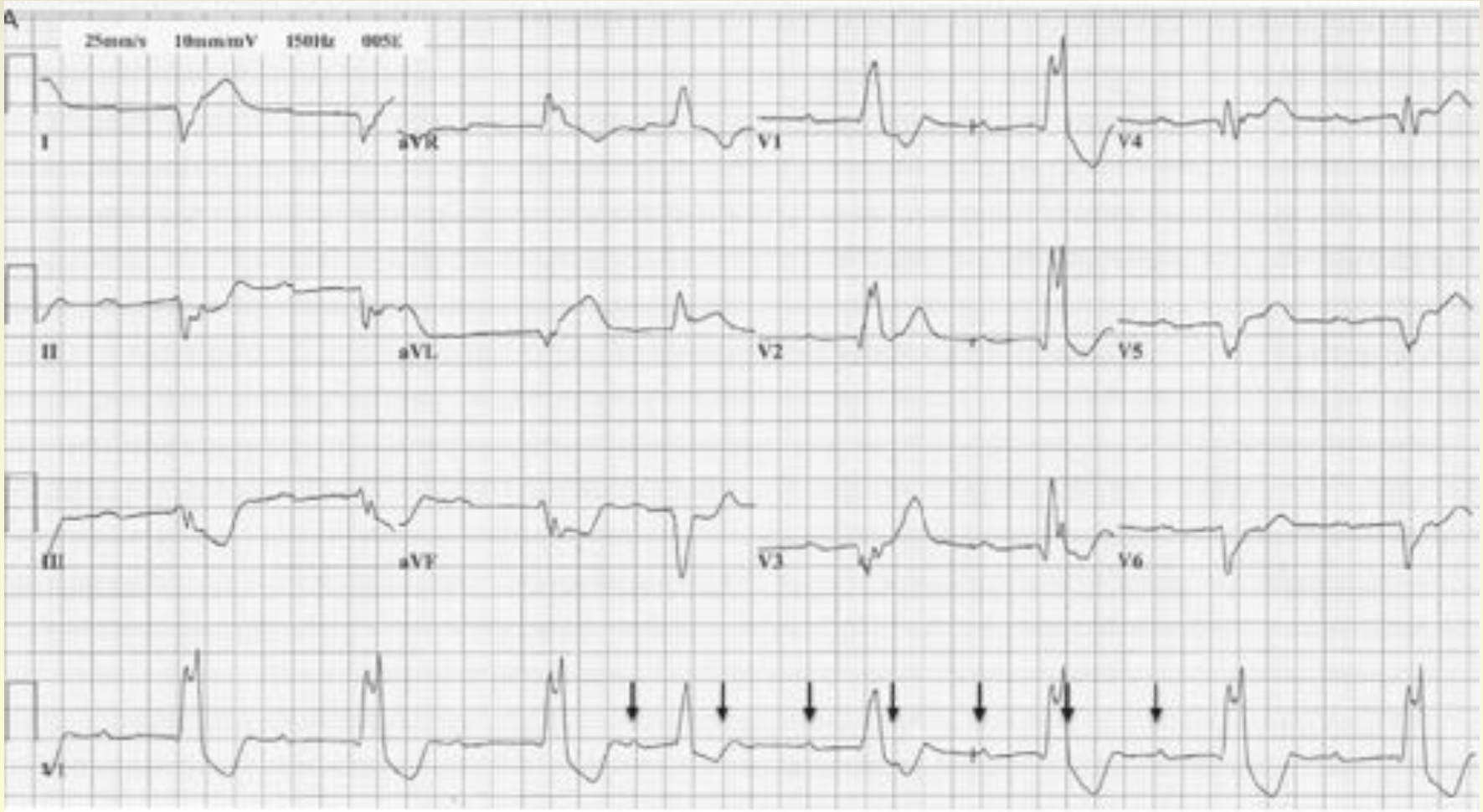
25mm/s 10mm/mV 150Hz 005E
I
aVR
V1
V4
II
aVL
V2
V5
III
aVF
V3
V6
V1

Disorders of the intraventricular conduction system in ACS

- Development of new bundle branch block: 5%- 15%
- New BBB is three times more likely during anterior infarction than during inferior infarction
- Acute MI + BBB: Mortality ↑ (in-and out of-hospital)

Domenighetti G, Perret C. Intraventricular conduction disturbances in acute myocardial infarction: short- and long-term prognosis. Eur J Cardiol. 1980;11:51–9.

BBB ????→ 3^0 Heart Block

- Acute MI + BBB:
  - 4 to 5 fold increased risk of progression to high grade AV block (increase from 4% to 18%)

Hindman MC et al. Circulation 1978; 58:679–88.
Hindman MC et al. Circulation 1978; 58:689–99.

BBB ???? → 3^0 Heart Block

Patient group	Risk of high-grade AV block
1^0 AV block + new bifascicular BBB	38-43%
1^0 AV block + old bifascicular BBB	20-50%
New bifascicular BBB	15-31%
Alternating BBB	44%

Lamas GA, *et al*. Am J Cardiol 1986; 57:1213–9

Indications for temporary transvenous pacing in acute myocardial infarction

Class I indications

1) Asystole.

2) Symptomatic bradycardia (includes sinus bradycardia with hypotension and type I second-degree AV block with hypotension not responsive to atropine).

3) Bilateral BBB [alternating BBB or RBBB with alternating left anterior fascicular block (LAFB)/left posterior fascicular block (LPFB)].

4 New or indeterminate age bifascicular block (RBBB with LAFB or LPFB, or LBBB) with first degree AV block.

5 Mobitz type II second-degree AV block.

2012 ACCF/AHA/HRS Focused Update Incorporated Into the ACCF/AHA/HRS 2008 Guidelines for Device-Based Therapy of Cardiac Rhythm Abnormalities

Indications for temporary transvenous pacing in acute myocardial infarction

Class IIa indications

1) RBBB and LAFB or LPFB (new or indeterminate).
2) RBBB with first-degree AV block.
3) LBBB, new or indeterminate.
4) Incessant VT, for atrial or ventricular overdrive pacing.
5) Recurrent sinus pauses (>3 s) not responsive to atropine.

2012 ACCF/AHA/HRS Focused Update Incorporated Into the ACCF/AHA/HRS 2008 Guidelines for Device-Based Therapy of Cardiac Rhythm Abnormalities

Indications for temporary transvenous pacing in acute myocardial infarction

Class IIb indications

1 Bifascicular block of indeterminate age.

2 New or age-indeterminate isolated RBBB.

Class III indications

1 First-degree heart block.

2 Type I second-degree AV block with normal hemodynamics.

3 Accelerated idioventricular rhythm.

4 BBB or fascicular block known to exist before acute MI.

2012 ACCF/AHA/HRS Focused Update Incorporated Into the ACCF/AHA/HRS 2008 Guidelines for Device-Based Therapy of Cardiac Rhythm Abnormalities

Permanent Pacemaker

The decision to implant a permanent pacemaker should

not to be taken lightly

- A permanent pacemaker is a life-long commitment for a patient
  - the need for a generator changes
  - surgical revisions for malfunctions

  become important considerations in younger patients.

Permanent pacing after the acute phase of MI

- Decision about permanent pacing must be made prior to the patient's discharge from the hospital.
  - the criteria for permanent pacing do not require the presence of symptoms in most of the patients
  - the need for temporary pacing in the acute stages of infarction is not by itself an indication for permanent pacing

Permanent pacing after the acute phase of MI

- Sinus node dysfunction tends to be benign and reversible, and permanent pacemakers are rarely required.
- 2^0 and even 3^0 AV block after inferior wall MI is usually reversible and rarely requires permanent pacing.
- However, conduction defects after an anterior wall MI usually warrant a permanent pacemaker or an ICD. *Mortality remains extremely high because of pump failure*

Permanent Pacing for AV Block Associated With Acute Myocardial Infarction

- Indications for permanent pacing after MI in patients experiencing AV block are related largely to the presence of intraventricular conduction defects.
- *Long-term prognosis for survivors of AMI + AV block:* related primarily to the extent of myocardial injury
- Development of an IVCD reflects extensive myocardial damage rather than an electrical problem.
- Patients with AMI + IVCD (except LAFB): poor prognosis, increased risk of sudden death

Permanent Pacing for AV Block Associated With Acute Myocardial Infarction

- *For the patient with MI and LVEF≤ 35%:*

if permanent pacing indicated....

CRT-D sholud be considered when improvement in LVEF is not anticipated.

Recommendations for Permanent Pacing After the Acute Phase of MI

CLASS I

1. Persistent 2^0 AV block in the His-Purkinje system with alternating BBB or 3^0AV block within or below the His-Purkinje system after ST-segment elevation MI

2. Transient advanced 2^0- or 3^0 degree *infranodal AV* block and associated BBB. If the site of block is uncertain, an electrophysiological study may be necessary.

3. Persistent and *symptomatic* second- or third-degree AV block

2012 ACCF/AHA/HRS Focused Update Incorporated Into the ACCF/AHA/HRS 2008 Guidelines for Device-Based Therapy of Cardiac Rhythm Abnormalities

Recommendations for Permanent Pacing After the Acute Phase of MI

CLASS IIb

1. Permanent ventricular pacing may be considered for persistent 2^0 or 3^0 degree AV block at the AV node level, even *in the absence of symptoms*

CLASS III

1. Permanent ventricular pacing is not indicated for *transient AV block* in the absence of intraventricular conduction defects.
2. *Transient AV block* in the presence of isolated LAFB
3. New BBB or fascicular block in the absence of AV block.
4. Persistent *asymptomatic* 1^0 AV block in the presence of BBB or fascicular block

2012 ACCF/AHA/HRS Focused Update Incorporated Into the ACCF/AHA/HRS 2008 Guidelines for Device-Based Therapy of Cardiac Rhythm Abnormalities

Thank you

for your attention